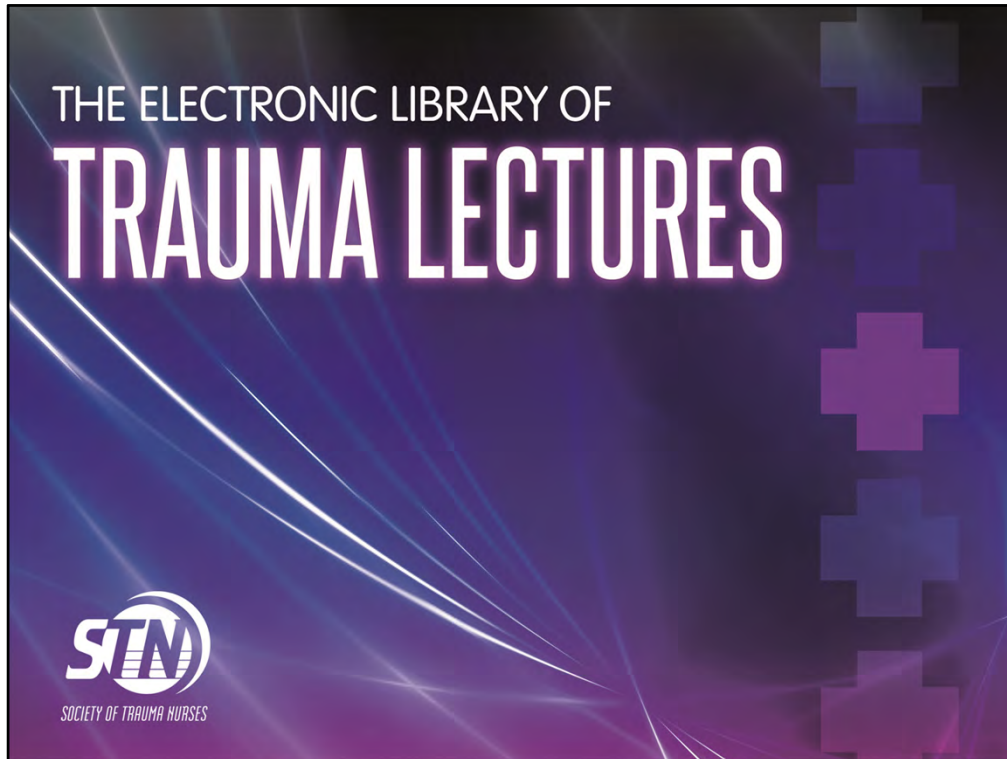



The evaluation and management of neck trauma has evolved over the past few decades. However, the challenges remain the same in that injuries to structures in the neck may cause life threatening situations or functional impairments.

## Objectives

**At the conclusion of this presentation the participant will be able to:**


- Examine the spectrum of neck trauma, the mechanisms of injury and associated injury patterns
- Define the three zones of the neck used as classifications of injury
- Identify the appropriate diagnostic modalities used to evaluate patients with neck trauma
- Explain the therapeutic interventions in the management of neck trauma
- Identify nursing interventions important in caring for patients with neck trauma



- This presentation covers neck trauma, excluding bony spine and spinal cord injuries.
- Overall, neck trauma is not a very common injury, however, there is no other place in the body where there is such a
- This lecture will review the mechanism of injury for neck trauma and anticipated injuries based on this mechanism.
- We will briefly discuss the diagnostic modalities used to identify neck injuries and the management of such, keeping in mind that bony injuries as well as cord injuries are outside of the scope of this presentation.
- Most importantly, we will talk about the nurse's role in recognizing physiologic changes, identifying occult injuries and providing quality care.

## Epidemiology

- 3500 deaths per year
- Mortality rate 2-6%
- Blunt mechanism accounts for 5%
- Penetrating trauma accounts for most
- Zone I injuries are the most lethal




- As previously stated, the small space of the neck is packed with vital vascular, enteric and neurologic structures, and although injuries are uncommon, the area is a very high risk area when injured. Airway occlusion and hemorrhage are the most immediate threats to life.
- Neck trauma occurs in 5-10% of serious trauma.
- Due to better diagnostics and management, mortality from neck trauma has improved over the past several decades and now is estimated to be 2-6%.
- Zone I injuries are the most deadly, and we will review the reasons why later in this presentation.

*immediate death*


*delayed death*

- Death from delayed diagnosis of neck injuries can be from exsanguination, loss of airway, or asphyxiation (in the case of strangulation), and infection due to missed aerodigestive injuries.
- Blunt trauma accounts for the smallest number of neck injuries. It is often caused by a rapid deceleration with the neck striking the steering wheel or dashboard.

## Epidemiology





- Commonly injured vessels
  - Internal jugular vein
  - Internal carotid artery
- Laryngeal and tracheal more common than pharyngeal and esophageal injuries



- As previously noted, the neck is a highly vascular region.
- The internal jugular vein and carotid arteries are the most common vessels injured.
- Injuries to the larynx and trachea are more common than injuries to the esophagus and pharynx because they are located anteriorly.
- The esophagus and pharynx are more protected since they lie between the airway and the spine

## Blunt Mechanism of Injury

- Steering wheel
- Assault
- Strangulation/Hanging
- “Clothes line” injuries
- Other (sports, industrial, etc.)



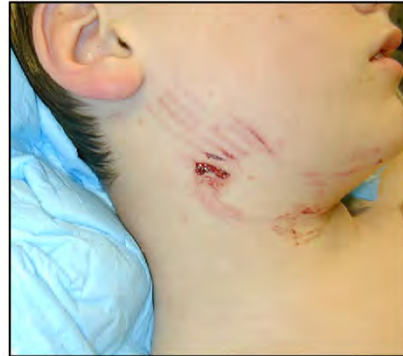- There are several blunt mechanisms for neck trauma, however, they usually occur as a result of a motor vehicle crash. Typically, the neck injuries are a result of the neck striking the dashboard or steering wheel.
- Clothes line injuries and/or tree limb injuries are more common in the upper Midwest where snowmobilers ride through the forests and farmer's fields.

The picture above shows a young man who was accidentally hung up in a flagpole line at school.



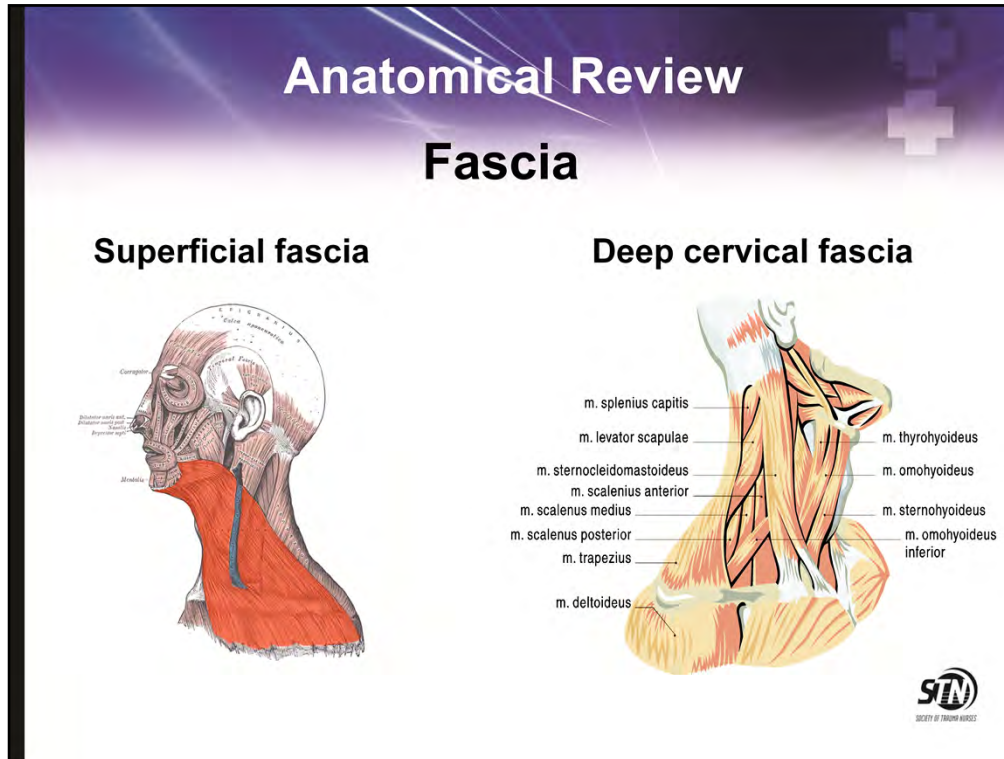
## Penetrating Mechanism of Injury

- Missile injury (bullet, knife, or other)
- Stabbing or lacerations
- Impalement
- Animal bites



- Penetrating injury is the most common cause of neck trauma and often results from GSWs and stabbings.
  - Gunshot wounds are generally more destructive than stab wounds and have a higher predictability for the need of operative intervention
- Velocity determines the predictability of the pathway.
- Low velocity bullets can meander through tissue often following an unpredictable pathway and causing injuries in unanticipated locations.
- Caution: the “apparent” entrance wound may be far away from where the bullet comes to rest in the body.
- Knife, buckshot, and BB guns have a decreased frequency of significant injury no matter which zone is involved.
- Less commonly seen injuries include impalement and animal bites.

This picture demonstrates a neck wound inflicted by a dog bite.



As previously noted, there is no other area in the human body where the number of vital structures exist in such a limited space.


Let's start with the basic review of the neck. Describe each and point out the structures on the diagram.

- The fascia is a structure of connective tissue that surrounds muscles, groups of muscles, blood vessels, and nerves, binding some structures together, while permitting others to slide smoothly over each other.
- The top layer of fascia is **superficial fascia**, which may be mixed with varying amounts of fat, depending on where it is on the body. The superficial layer contains the platysma, (pronounced PLAH-tiz-ma) which is the thin muscle sheath in the subcutaneous tissue of the neck. It originates in the fascia of chest and shoulder. It inserts at the fascia of the face, lower jaw, and corners of the mouth. It's action is that it wrinkles the skin of the neck and upper chest. It's nerve supply is from the cervical branch of the facial nerve.
- The platysma is an important surgical landmark, and penetration has historically signified the need for surgical exploration. However, formal neck exploration for all penetrating trauma that violates the platysma in stable patients is considered the "old standard" as it was associated with a 50% negative exploratory rate. New focus on directed exams: angiography, esophagoscopy, esophagography, laryngoscopy.
- **Deep fascia** surrounds the muscles, bones, nerves and blood vessels of the body. It is less extensible and essentially avascular, however, it is richly innervated with sensory receptors that signal the presence of pain, a change in movement, a change in pressure and vibration, a change in the chemical milieu, and fluctuation in temperature. Deep fascia is able to respond to sensory input by contracting; by relaxing; or by adding, reducing, or changing its composition through the process of fascial remodeling.
- Deep fascia:
  - Investing: sternocleidomastoid muscle, trapezius muscle
  - Pretracheal: larynx, trachea, thyroid gland, pericardium
  - Prevertebral: prevertebral muscles, phrenic nerve, brachial plexus, axillary sheath
  - Carotid sheath: carotid artery, internal jugular vein, vagus nerve
- Tight fascial compartments of neck structures may limit external hemorrhage from vascular injuries, minimizing the chance of exanguination, an apparently beneficial effect that is countered, however, by the effects of bleeding within these closed compartments, which frequently compromises the airway.

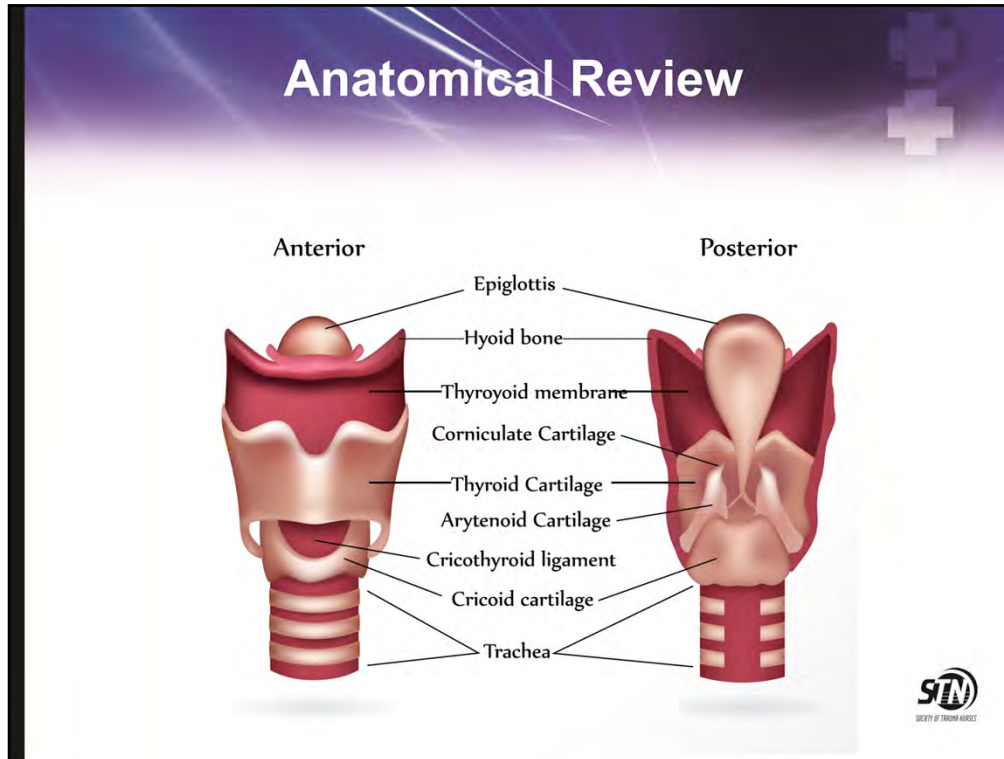

## Structures at Risk

<b>Musculoskeletal</b>	<b>Glandular</b>
<ul style="list-style-type: none"><li>• Vertebral bodies</li><li>• Cervical muscles and tendons</li><li>• Clavicles, 1<sup>st</sup> and 2<sup>nd</sup> ribs</li><li>• Hyoid bone</li></ul>	<ul style="list-style-type: none"><li>• Thyroid</li><li>• Parathyroid</li><li>• Submandibular</li><li>• Parotid glands</li></ul>



Many structures from various body systems are found within a very small space.



Note that the larynx and trachea are the most anterior structures and the most likely to be injured first.

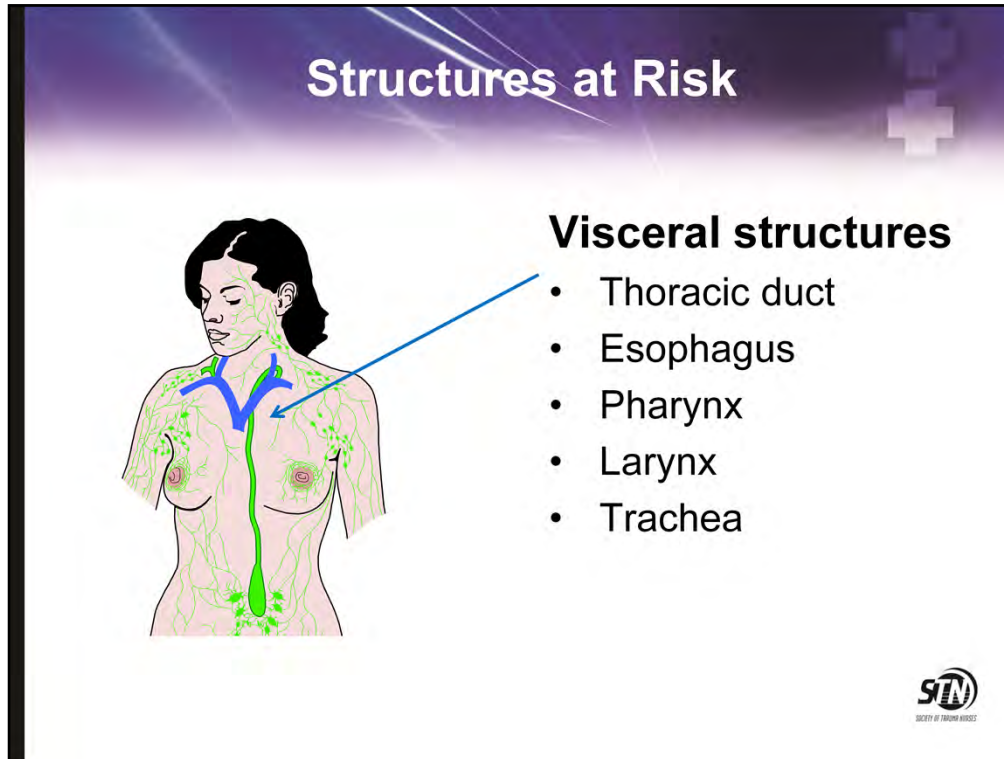
This could be by either blunt or penetrating injury, but most commonly it is a blunt mechanism of injury.

When the head/neck are held in a neutral position:

Hyoid bone = level C3

Thyroid cartilage = C4

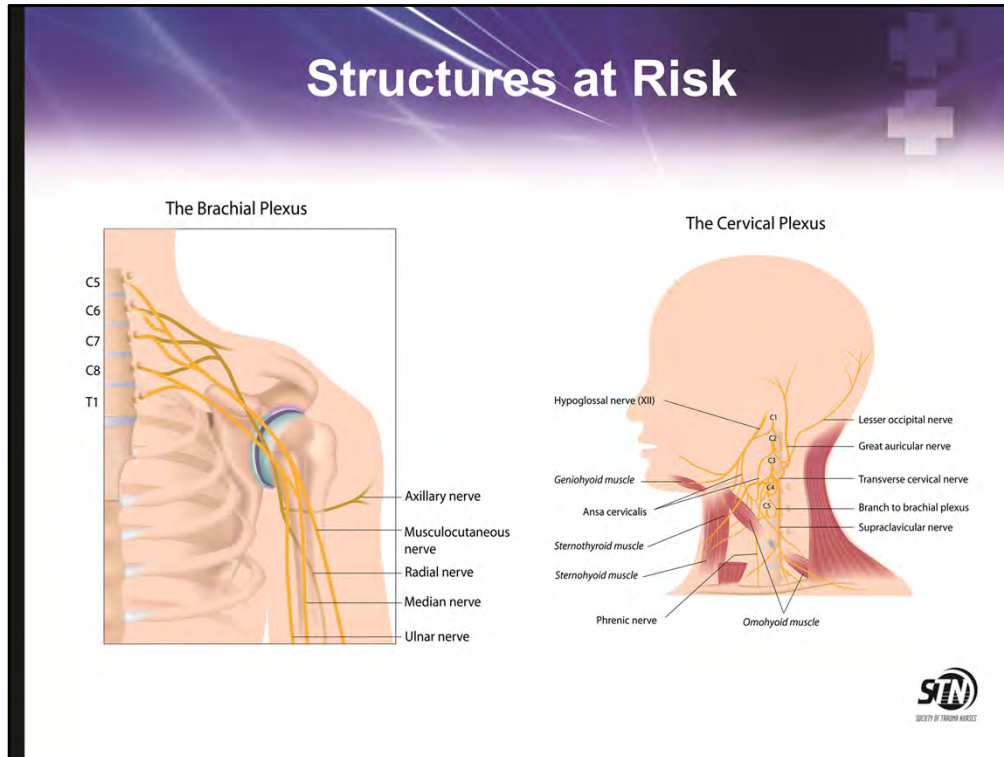
Cricoid cartilage and the esophagus begins around C6



#### Visceral

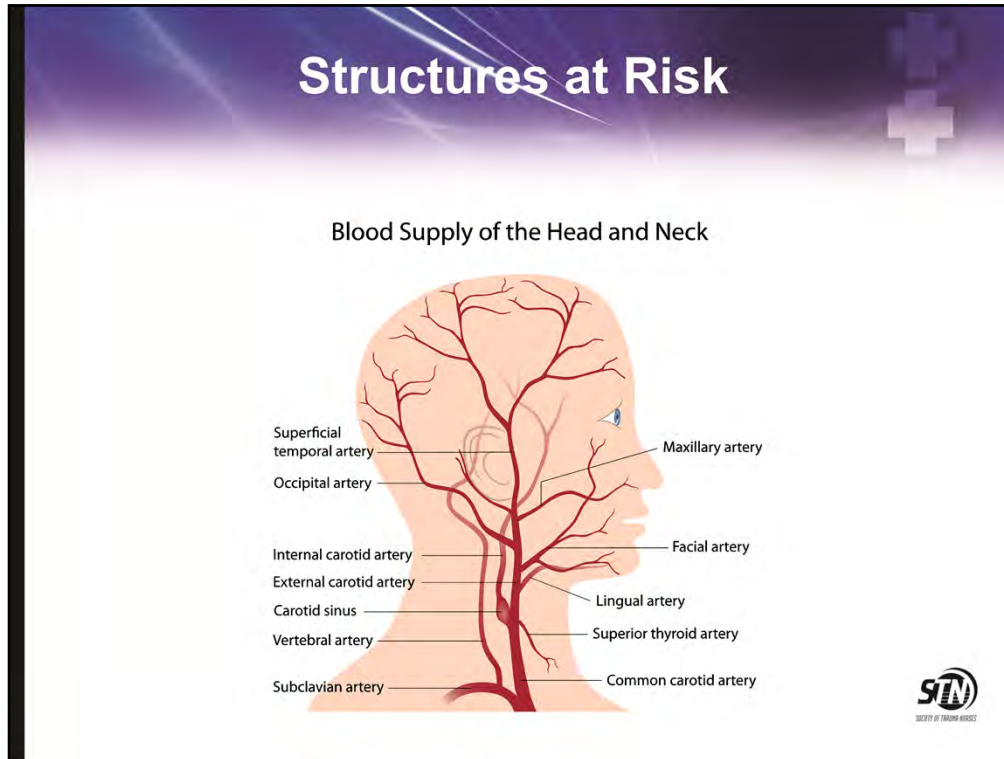
- The thoracic duct is important because it drains lymph from the majority of the body into the right and left subclavian veins (except that from the right arm and the right side of the chest, neck and head, and lower left lobe of the lung, which is collected by the right lymphatic duct).
- Esophagus – originates at end of laryngopharynx (C6 level).
  - Injury is rare. When at rest, the esophagus relaxes and decreases in size making it small and less prone to injury
  - The majority of injuries occur secondary to penetrating trauma and usually involve the cervical portion of the esophagus (95%). Prompt diagnosis and management is critical to minimizing mortality.
  - A delay of greater than 24 hours in diagnosis and treatment of an esophageal perforation is associated with a higher mortality rate compared with an early diagnosis and treatment initiation.
  - The mortality rate following operative management of an esophageal perforation is dependent on location of the perforation, with cervical perforations having the lowest mortality rate (6 percent) compared with thoracic perforations (27 to 34 percent), and intra-abdominal perforations (21 to 29 percent).
  - Other causes: Barotrauma is a rapid change in the pressure of the esophagus which leads to tearing or perforation. Examples of this includes blast injuries. Another example of barotrauma is Boerhaave's syndrome where a patient vomits against a closed glottis, resulting in increased pressure in the esophagus causing perforation. Crush injuries are also another mechanism for blunt esophageal injury as are blows to the neck during fights/boxing matches.

Tracheal injury may accompany blunt esophageal trauma because the trachea is located more anteriorly.



### Nervous

- The phrenic nerve contains motor, sensory, and sympathetic nerve fibers. These nerves provide the only motor supply to the diaphragm. In the thorax, each phrenic nerve supplies the mediastinal pleura and pericardium. Injuries to the phrenic nerve can cause paralysis of part of the diaphragm that it innervates
- The brachial plexus – supplies cutaneous and muscular innervation of the entire upper limb, with the exception of the trapezius muscle and the area of skin near the axilla innervated by the intercostobrachial nerve
- The recurrent laryngeal nerve is the motor nerve to the larynx –supplying all of its muscles, except that of the cricothyroid muscle. Injury to this nerve causes paralysis of the vocal fold. The voice is impaired because the paralyzed side cannot meet the normal side. Hoarseness is the most common symptom.
- Cranial nerve injury – can be identified by tongue deviation, (CN XI)
- Stellate ganglion is located at the level of C7, anterior to the transverse process of C7, anterior to the neck of the first rib and just below the subclavian artery. The ganglia can be cut in order to decrease the symptoms exhibited with Raynaud's' disease and hyperhydrosis (extreme sweating) of the hands. Injection of local anesthetics near the stellate ganglion is sometimes used as a pain management technique.
- Complications associated with a stellate ganglion block include Horner's syndrome, difficulty swallowing, vocal cord paralysis, and pneumothorax.



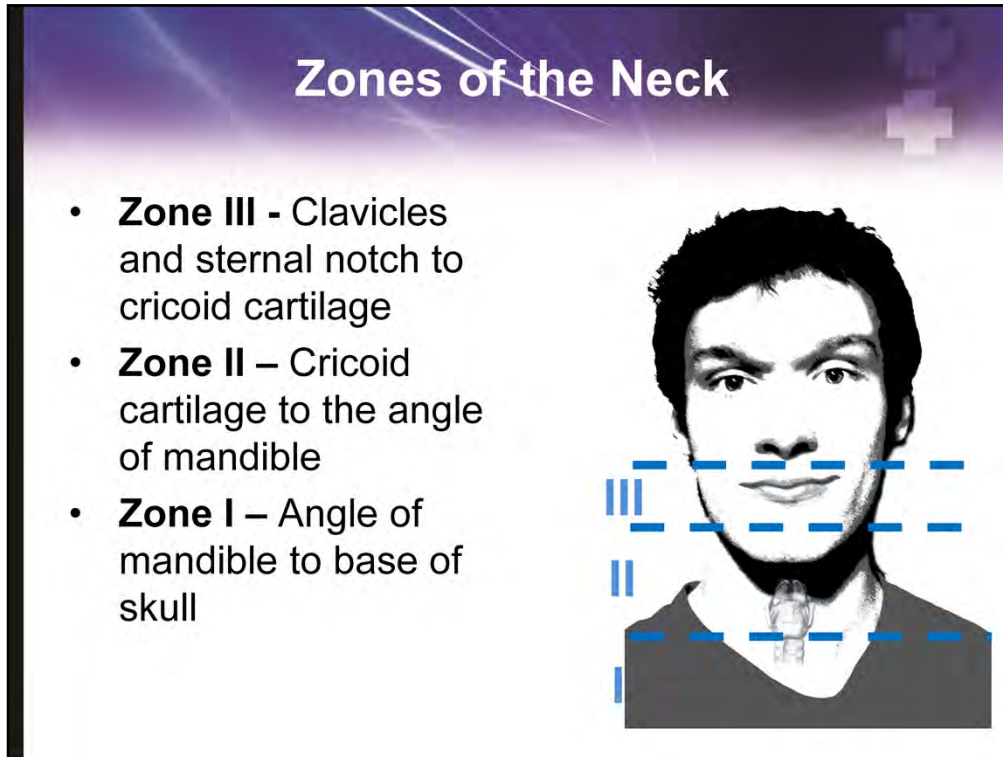
The major blood vessels are situated between the spine and the airway structures

The internal jugular and carotid arteries are the most commonly injured vessels.

The larynx and trachea, because they are so anterior, are the most readily injured structures.

The spinal cord is posterior and well protected by the vertebral bodies, muscles, and ligaments.





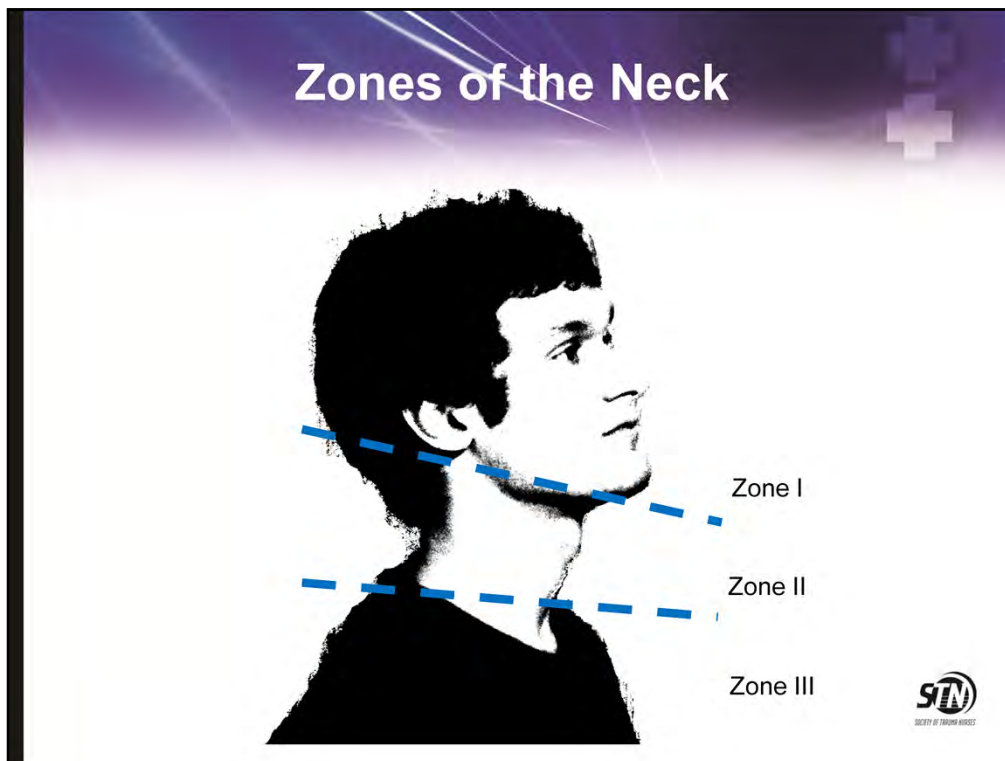
- First divided into zones in a paper from Monson *et al* Cook County Hospital 1969

Zone I - Cricoid cartilage to the thoracic inlet (clavicles to cricoid)

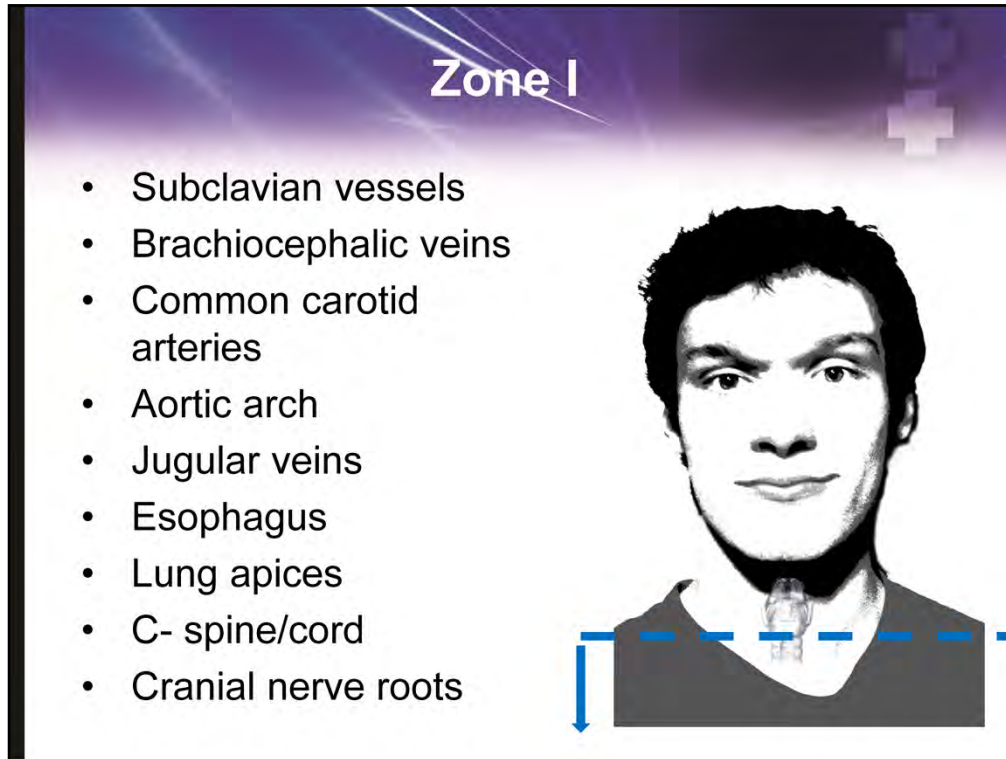
Zone II – cricoid to angle of the mandible

Zone III – angle of the mandible to the base of the skull

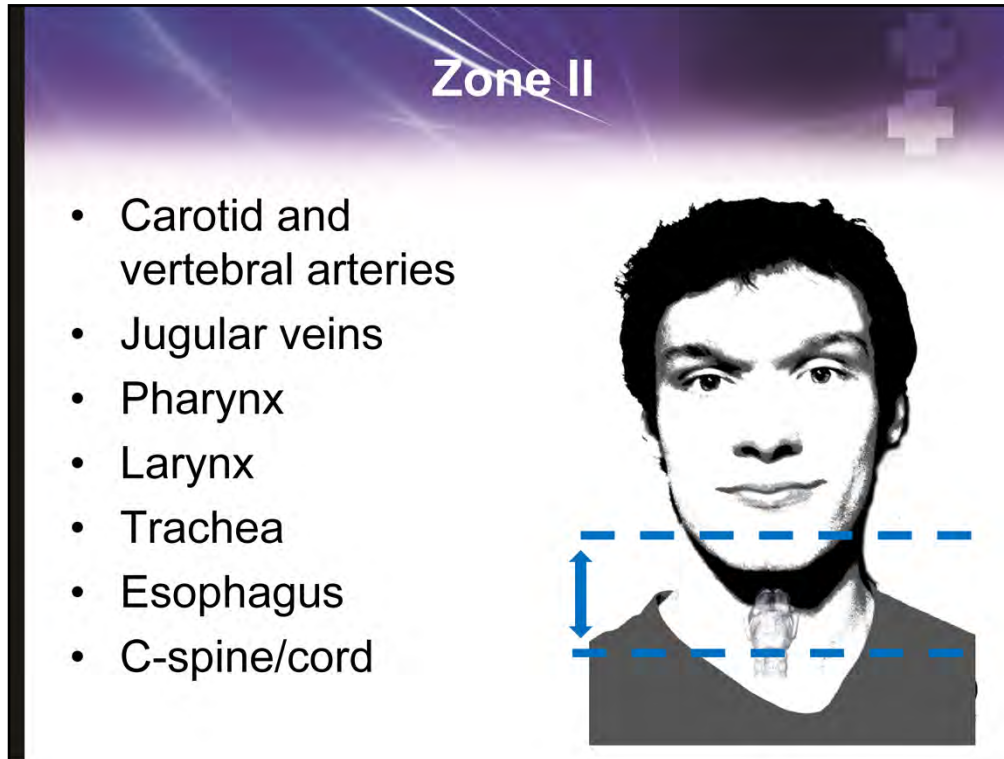
- Some modern day references are steering away from “zones” and hint at their being outdated for the following reasons:
  - Location of skin wound not a reliable indicator of underlying injuries
  - Length of neck makes it impractical to divide into three short zones
  - Wounds often occur at border between zones and difficult to classify
- Regardless, they are still widely used to provide a standardized point of reference for assessing and diagnosing injuries in the neck. Surgeons categorize neck injuries according to the “Zone” of injury
- Guidelines (to be discussed later) are designed around the zone of injury. For example, injuries in Zone 3 are markedly different than those in Zone 1.



This shows a lateral view of the 3 anatomic zones of the neck.



- Zone 1 extends from the base of the neck (thoracic inlet inferiorly and the cricoid cartilage superiorly).
- **Difficult to assess on physical exam** because these structures are often hidden in the exam of the chest or mediastinum.
- As mentioned earlier, Zone I injuries have the highest mortality.
- Adequate exposure for exploration and repair may require sternotomy, clavicle resection, or thoracotomy
- High morbidity of exploration, thus suspicion must be great before taking the patient to OR
- Cardiothoracic surgery consultation
- Angiography is essential for roadmap

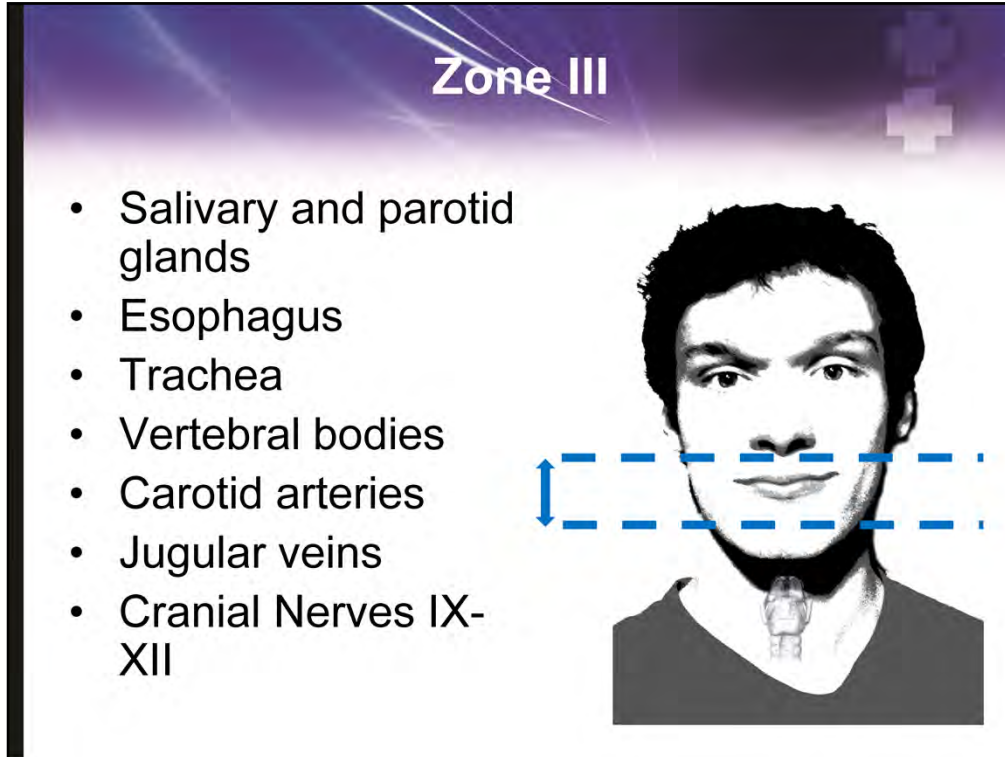


- Zone II includes the midportion of the neck and extends from the cricoid cartilage to the angle of the mandible
- ***Injuries apparent on physical exam. Most carotid artery injuries are in Zone II.***

Few injuries will escape clinical examination

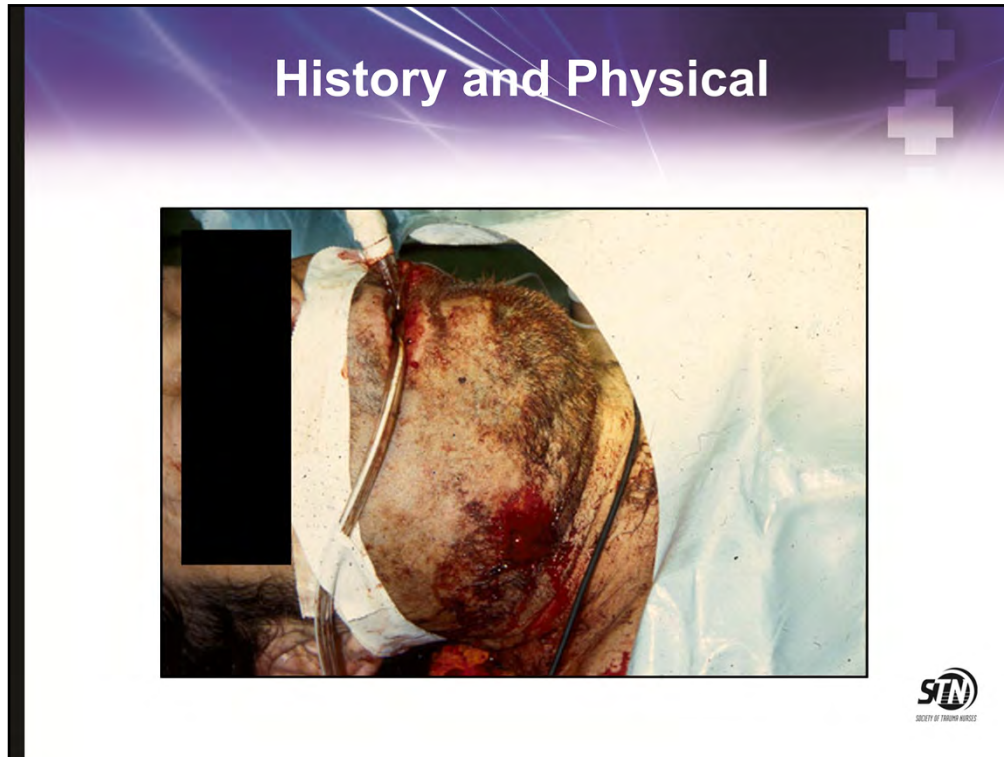
Most carotid injuries occur here

Some symptomatic zone II injuries can generally be selectively managed by observation



- Extends from the angle of the mandible to the base of the skull. Zone III injuries to vascular structures are hard to access surgically, because they are so high in neck/at skull base.
- Identification of esophageal injuries early is imperative. Survival from esophageal injuries is high if identified within 24 hours, but drops dramatically if identified after 24 hours because of mediastinal infection.
- High rate of vascular injury, often multiple
- Often difficult to obtain proximal and distal vessel control
- Exploration has high rate of injury to cranial nerves
- Adequate exposure may require mandibular subluxation or mandibulotomy
- Angiography needed to delineate site of injury
- Embolization techniques of greatest value here







- The nurse has a very vital role in ascertaining the history of the incident and completing a comprehensive physical exam.
- It is not uncommon, especially in the case of penetrating trauma, for a stab wound or gunshot wound to be “hidden” underneath a dressing or cervical collar. Note here that this injury might be hidden if the patient had on a cervical collar.
- In assessing the history, it is imperative to identify if the patient takes anticoagulants. Minor blunt or penetrating neck trauma in anticoagulated patients can lead to airway compromise from expanding neck hematomas.

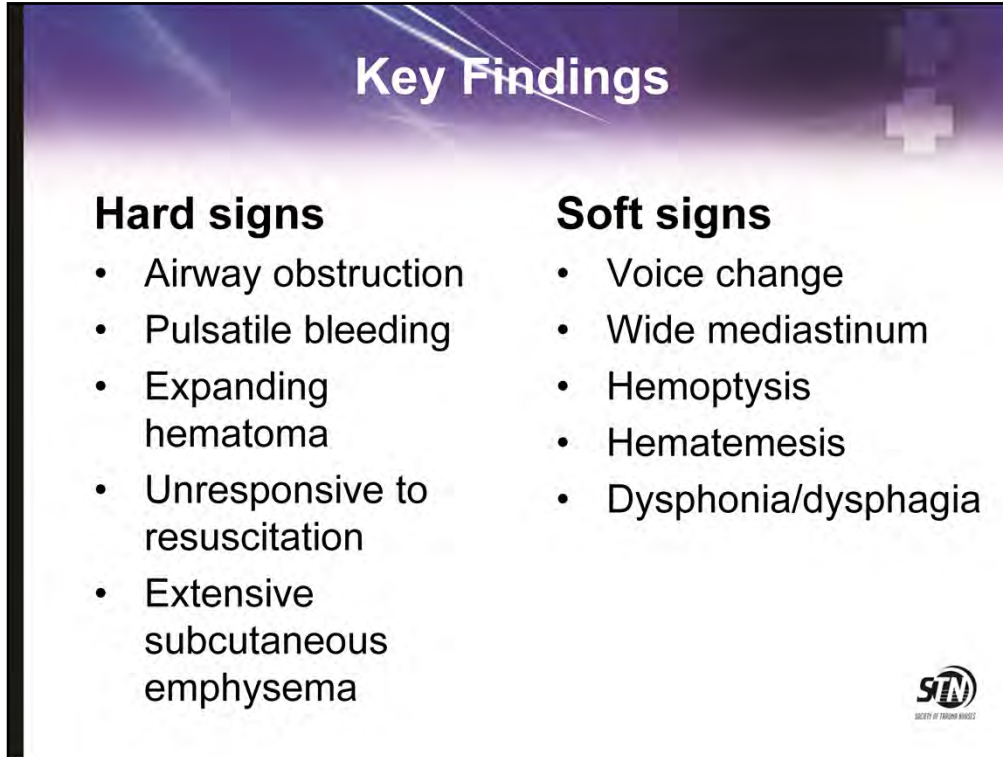
## History and Physical

- Gun
  - Caliper, distance
- Knife
  - Length, angle
- Amount of blood loss
- Baseline mental status
- Baseline motor status
- Drug or alcohol use




For penetrating trauma:

- Obtain history
  - Type of gun or knife
  - Amount of blood loss at scene
  - Patient's baseline mental status
  - Recent drug or ETOH ingestion
- The velocity of the weapon is very important, as previously mentioned. In this case, the velocity of a knife is low, and the path of the knife is obvious.
- The patient's baseline mental status is very important to be able to assess for signs of stroke from a carotid or vertebral artery injury. Carefully record the GCS and note extremity movement in all four extremities or deficits, unilateral weakness
- Recent drug or ETOH ingestion might alter their mental status and injury to the cerebral vessels should be ruled out before the mental status changes are attributed to alcohol or drug effects.



## Key Findings

<b>Hard signs</b>	<b>Soft signs</b>
<ul style="list-style-type: none"><li>• Airway obstruction</li><li>• Pulsatile bleeding</li><li>• Expanding hematoma</li><li>• Unresponsive to resuscitation</li><li>• Extensive subcutaneous emphysema</li></ul>	<ul style="list-style-type: none"><li>• Voice change</li><li>• Wide mediastinum</li><li>• Hemoptysis</li><li>• Hematemesis</li><li>• Dysphonia/dysphagia</li></ul>




As we proceed to assessment of the ABCs, there are two groups of signs important to note. Hard and Soft signs.

Obviously, hard signs indicate emergency conditions needing intervention.

And, soft signs provide key information as well but will allow more time to perform diagnostics.

## Management - Primary Survey

- ABCs
- Ensure airway is patent
- Ensure patient is adequately oxygenating
- Control any obvious hemorrhaging
- IV access



Perform the ABCs as you would with any trauma patient.

Also, remember the trajectory. An external wound is just that...internally, the wound may be more extensive or in the case of a missile, damage to a different area should be considered.

Stabilize the airway / breathing

- Be prepared to obtain an airway emergently
- Intubation or cricothyroidotomy
- Beware of cutting the neck in the region of the hematoma -- disruption there of may lead to massive bleeding
- Must assume cervical spine injury until proven otherwise

Stop the bleeding

- Bleeding should be controlled by pressure
- Do not clamp blindly or probe the wound depths
- The absence of visible hemorrhage does not rule out an injury
- Appropriate IV access; Careful of IV in arm unilateral to subclavian injury
- Remember concept of "permissive hypotension" during resuscitation

## Airway Considerations

Who requires immediate intubation?

- Apneic
- Comatose
- Respiratory compromise
- Expanding neck hematoma
- Massive subcutaneous emphysema
- Massive bleeding in airway




- Obviously, those patients who cannot protect their own airway are at risk whether they are not breathing, are unconscious or have massive secretions and blood within the airway.
- Patients suffering from compromise and are demonstrating symptoms related to the injury itself e.g. hoarseness, dysphonia, dysphagia
- Subcutaneous emphysema can cause compression of airway; distortion of trachea or larynx




## Airway Considerations

- “Wait and See”
- Avoid excessive bag-valve-mask
- Exercise caution with paralytics and sedation
- Surgical airway last resort
- Cricothyrotomy vs. tracheostomy




- Then there are patients who some may elect to “wait and see” if they are maintaining an airway rather than risk making matters worse.
- Although ventilation by BVM is certainly acceptable and sometimes necessary, some would advise the avoidance of BVM if possible because positive pressure generated by BVM may increase air leak through a disrupted airway and cause or increase massive subcutaneous emphysema with distortion of the airway and further airway compromise; BVM may also cause excessive neck movements in an uncooperative patient with increased bleeding from contained hematoma. When used, gentle ventilation and heightened awareness to minimize harm is essential.
- RSI oral intubation is technique of choice
- If difficult intubation anticipated, be cautious about medications administered, e.g. paralytics, under/oversedation, etc.
- Surgical airway is last resort but there may be no other option
- Evaluation of injuries will determine which airway is appropriate - cricothyroidotomy or tracheostomy

## Control Bleeding

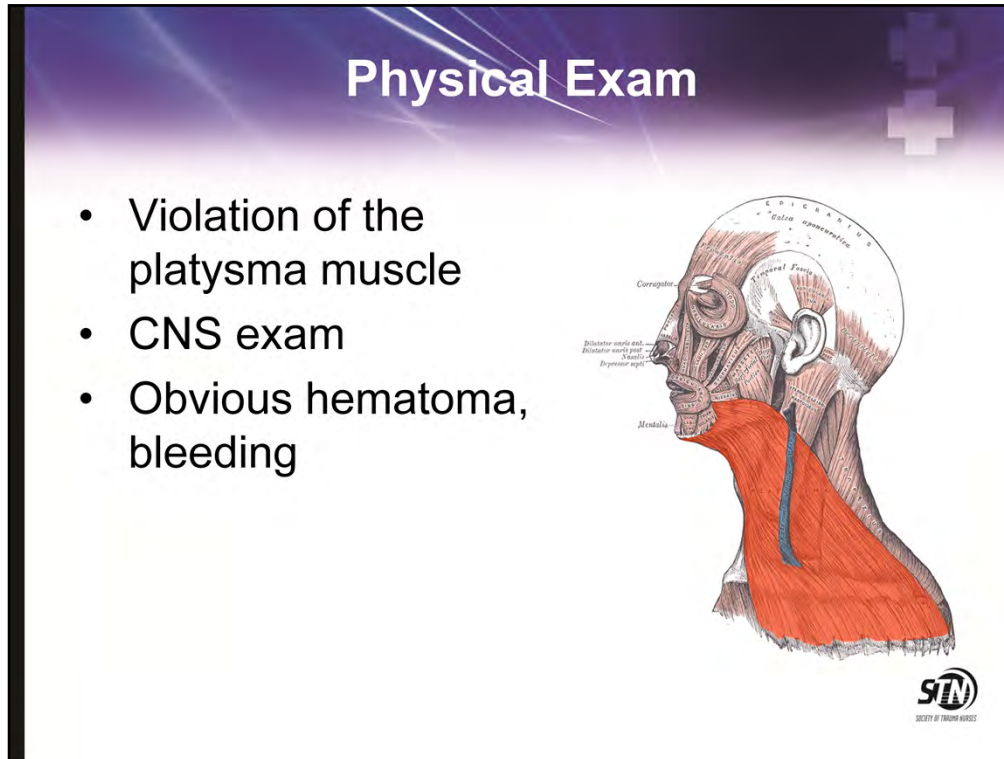


- Local pressure only
- **No** tourniquets
- **No** pressure dressings
- **No** probing or blind clamp placement

<http://chestofbooks.com>





- Local pressure: minimal amount of pressure should be applied to any wound to avoid any necessary compression of ipsilateral carotid artery.
- 10-30% of patients do not have sufficient collateral circulation to guarantee sufficient ipsilateral collateral anterior cerebral circulation blood flow.
- Creative methods to tamponade bleeding may be needed temporarily e.g. Foley catheters through wound along wound tract in direction of apparent bleeding source with inflation of balloon with saline until bleeding stops or moderate resistance felt.



- Assess for violation of the platysma muscle. Injury of the platysma indicates high risk of serious injury.
- Do not probe wounds; Platysma penetration mandates evaluation in controlled fashion
- A disadvantage of operatively exploring all penetrating neck injuries with platysma violation is 50% are nontherapeutic which results in unnecessary risks to patient and costs.
- Some advocate selective operative intervention for Zone II.
- Assess for hoarseness, dysphonia, dysphagia. Dysphonia is most commonly demonstrated by hoarseness or a “breathy” voice.
- Dysphagia is difficulty swallowing. The patient may have drooling because he is unable to swallow his own secretions
- CNS exam looking for weakness, paralysis
- Assess for obvious hematoma, bleeding
- Over 95% penetrating wounds result from knives and guns.
- Surgery is usually indicated in 75% cases involving a gun; 50% stab wounds require exploration

## Physical exam

- Contusions, lacerations, abrasions to the neck, etc.
- Expanding hematomas, obvious bleeding
- Hoarseness, stridor,
- Subcutaneous emphysema
- Hemoptysis, drooling
- Dyspnea
- Distortion of the normal anatomic landmarks
- Mandibular/midface instability



•The trauma nurse needs to maintain a high index of suspicion if the patient demonstrates any hoarseness, inability to manage their secretions and subjective signs of shortness of breath. These can all be signs of vascular, laryngeal, tracheal, or other soft tissue injury.

•Clinical cues include dysphagia, odynophagia, drooling and hematemesis (bloody sputum)



•Evaluate for hematomas, bruit, thrill, Horner's syndrome, limb paresis or paralysis, deep coma.

•This patient is at high risk for a tracheal injury and airway compromise

PITFALL: Failure to consider blunt carotid injury with negative CT and CNS changes delayed

## Diagnostic Studies

- Chest radiograph
- CT and CT angiogram
  - Laryngeal injury
  - Tracheal injury
  - Vessels
  - Blunt esophageal injury




- CXR – any finding of a zone I injury mandates a CXR. The film should be reviewed for hemothorax, pneumothorax, widened mediastinum, mediastinal emphysema, foreign bodies, etc.
- CT is most accepted imaging. In most trauma centers, CT or CTA has replaced the more invasive conventional angiography, especially with newer generation, multidetector helical scanning that have increased the sensitivity and specificity for certain injuries (e.g. Blunt carotid injury) and provide excellent images.
- Multidetector, helical CT scanners have improved and can provide valuable information for a variety of injuries.
- Some believe that the subtle variances in the vessel wall may be more easily detected with reconstructions on CTA
- Blunt trauma - Excellent study for laryngeal and tracheal injuries.
- Good sensitivity and specificity for the detection of vascular injuries such as the carotid arteries. The literature notes that 16 slice or greater CTA is reliable in diagnosing blunt cerebrovascular injury consistent with the reliability of arteriography.
- May identify extraluminal air in the case of esophageal injury. However, there are no current studies or data which support CT as the **sole** diagnostic tool in the evaluation of esophageal injury.
- Advantage is that it can be done at the same time the trauma patient is getting other scans and this minimizes the dye load which can be up to 50% less than used with full arch aortogram and 4-vessel study.



## Diagnostic Studies

### CT Scan

- Can aid in identifying weapon trajectory and structures at risk
- Should only be used in stable patients
- Gracias *et al* (2001) found that use of CT scan in stable patients
  - Saved patients from arteriogram indicated by older protocols 50% of the time
  - Avoided esophagoscopy in 90% of patients who might otherwise have undergone it



- Obviously physical exam is key in any trauma patient assessment. The ABCs should be addressed with securing an airway and stopping bleeding.
- Any patient with active hemorrhage or expanding hematomas who is hemodynamically unstable should go to the OR as there is no time for imaging.
- If the patient is stable, it is helpful to have images for zones I and III as these are difficult areas to access and the imaging may provide a “roadmap” of the most appropriate option of exploration.

Gracias *et al* – metallic markers @ skin entry sites, skin violation, subQ fat stranding, soft tissue air or hematoma, vertebral fracture, contrast extravasation, missile location.



## Diagnostic Studies

- Laryngoscopy
- Bronchoscopy
- Esophagoscopy;  
esophagram
- Rigid vs. flexible  
esophagoscopy
- Color flow doppler,  
duplex ultrasonography
- MRA



- Laryngoscopy and bronchoscopy provides direct visualization of the larynx and trachea, however, ETT may obscure portions and one must be careful to fully evaluate and not make assumptions.
- Bronchoscopy provides the single definitive tool to evaluate the injured airway and may be useful in guiding intubation.
- Esophagram – Gastrografin or barium can be used. Gastrografin results in pneumonitis if aspirated. Barium causes increased inflammation/infection in the mediastinum.
- Flexible esophagoscopy provides good visualization of the mid and distal portions of the esophagus, and, rigid scope may also be used successfully. May not find small injuries if esophagus is not adequately distended.
- Color flow doppler studies/duplex ultrasonography can detect vascular injuries and is noninvasive but it does have limitations. It can be considered the imaging modality of choice for **extracranial carotid artery** injuries, however, is inaccurate at base of skull and relies on flow disturbances. Utility for BCVI has not been proven effective.
- MRA can be useful in stable patients. It is time consuming, has a low sensitivity and specificity for blunt cerebrovascular injuries, requires MRI-compatible life-support devices, and it is not universally available. Although its efficacy is not yet proven, it is appropriate in patients who are already going for MRI cervical spine. Other advantages include the avoidance of iodinated contrast and earlier detection of injuries since bony artifact is eliminated.

## Diagnostic Studies


### Arteriogram

- Gold standard
- Invasive
- Complications
- Availability varies
- Expensive
- Contrast load
- Simultaneous intervention




- Historically, 4-vessel biplanar digital subtraction arteriography has been the gold standard for detecting carotid and vertebral injuries as its sensitivity and specificity is close to 100%
- It is invasive and therefore, other options are being considered as technology continues to advance.
- There are complications associated with it, site complications, e.g. hematoma, pseudoaneurysm, as well as those from the procedure itself, e.g. contrast allergy, contrast nephropathy, and stroke.
- Moreover, it is expensive and may not be available 24/7/365.
- Currently, CTA has largely supplanted its use and this is reserved for further evaluation if CTA is negative or equivocal and the suspicion for injury remains high
- An advantage is that therapeutic interventions such as embolization may be performed at the same time when indicated.

## Specific Injuries



- Vascular
- Aerodigestive
- Cranial nerves
- Thoracic duct



- Types of neck injuries found with both penetrating and blunt mechanisms
- There are many structures that can be injured in the 3 zones of the neck. These are the most common injuries that we will focus on for this lecture
- Most common vascular injuries are the carotid, vertebral, jugular vessels. Collectively, these areas for injury are referred to as cerebrovascular injury.
- Aerodigestive injuries include: Trachea, Larynx, Esophagus, and Pharynx


15 year old who had his throat slashed and carotid artery lacerated with resulting exsanguination at scene.

- Due to the close proximity of many structures, injuries may occur to more than one area.

## Vascular Injuries in the Neck

**Physical Exam**

- External marks
- Decreased LOC
- Hemiparesis
- Hematoma
- Hypotension
- Dyspnea
- Thrill, bruit, pulse not present



**STN**  
SOCIETY OF TRAUMA NURSES

Vascular injuries involve the carotid artery (common, internal and external) the subclavian and vertebral arteries and the vertebral, brachiocephalic, and jugular (internal and external) veins. Vascular injuries are not always obvious and if delayed may lead to complications.



The trauma nurse is often the first individual to identify signs of an undiagnosed cerebral vessel injury. These findings of decreased level of consciousness and hemiparesis can be confusing and confounded by brain injury or drug/alcohol intoxication.

- Regardless if the mechanism is blunt or penetrating, there are some key things to note on physical exam.
- It is important to note that only 10% of blunt trauma patients will develop symptoms within the first hour.
- Any decreased level of consciousness not explained by a traumatic brain injury or presence of intoxicants can indicate a potential vascular injury. Changes in level of consciousness can be related to “blossoming” of an intracranial bleed or a stroke due to occlusion of one of the major vessels in the neck. It is imperative that a baseline mental status be well documented on arrival of the patient.
- Hemiparesis is very concerning for vascular injury. Look for external contusions, abrasions like these seatbelt marks on this patient’s neck in Zone I and III.
- Dyspnea due to the compression of the trachea
- Bruits (essentially an arterial murmur or “swishing or “blowing” sound can be heard at the posterior margin of the sternocleidomastoid muscle and are often heard with obstruction of the carotid artery.
- A thrill is heard or felt in the same area and is a vibration caused by turbulent blood flow.

The injury noted in this photo would prompt a CTA of the neck in most trauma centers

## Associated Injuries

- Le Fort II or III fractures
- Basilar skull fracture involving the carotid canal
- Diffuse Axonal Injury with GCS < 6
- Cervical vertebral body fracture
- Near hanging with anoxic brain injury
- Seatbelt abrasion of anterior neck with significant swelling/altered mental status



There are several associated injuries that should raise your index of suspicion for vascular involvement (Blunt Neck Trauma)

These criteria are based on the “Denver Screening Criteria” for blunt cerebral vascular injury

Of note, cervical spine fractures involving the transverse foramen are particularly high risk for vertebral artery injury and subsequent stroke.

Please reference the EAST guidelines at [www.east.org](http://www.east.org)



The info is consistent to what has been presented

Blunt injuries of the carotid and vertebral arteries appear to be more common than previously suggested. Early diagnosis and treatment of these injuries improves neurologic outcome. Aggressive screening protocols may increase the diagnosis of these injuries; the failure to diagnose and treat these lesions may result in a devastating and permanent neurologic injury



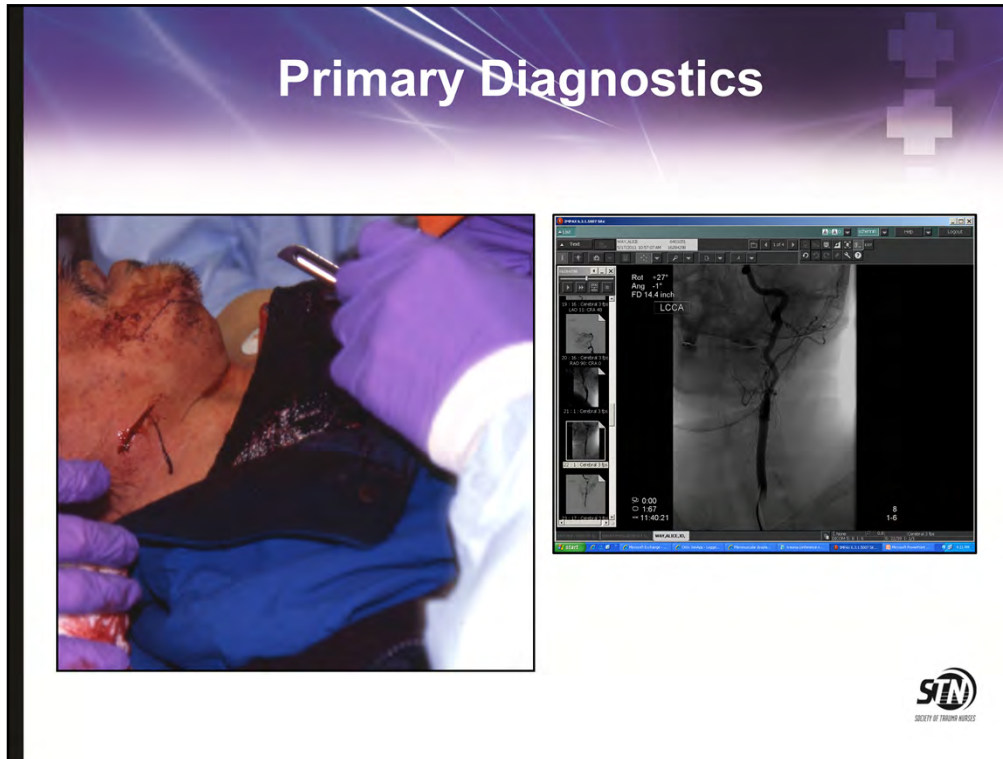
## Primary Diagnostics

- CT angiogram of the neck
- Chest x-ray indicated in Zone I injuries because of their proximity to the chest
- Complete blood count, basic metabolic panel, toxicology and blood alcohol content



CT angiogram is the most common way to diagnose BCVI's in most institutions. The gold standard is an angiogram, however, the literature supports the use of CT angiogram especially given the advances in multidetector, helical scanners. A chest x-ray is important to rule out pneumothorax or other chest pathology. The other labs are drawn either routinely or as specifically ordered according to individual trauma center protocols.






Order of diagnostics depends on the severity of other life-threatening injuries and if the patient requires emergent operative intervention  
If the patient is bleeding to death from a splenic injury, the CT angiogram may have to wait until the splenic injury is addressed.

## Vascular Injury Management

- Common carotid: repair preferred over ligation in almost all cases
- Internal carotid: Shunting is usually necessary
- Vertebral: Angiographic embolization or proximal ligation can be used if the contralateral vertebral artery is intact
- Internal Jugular: Repair vs. ligation



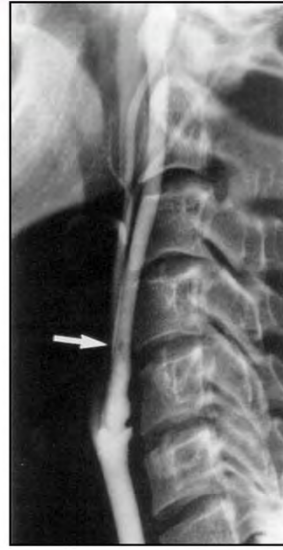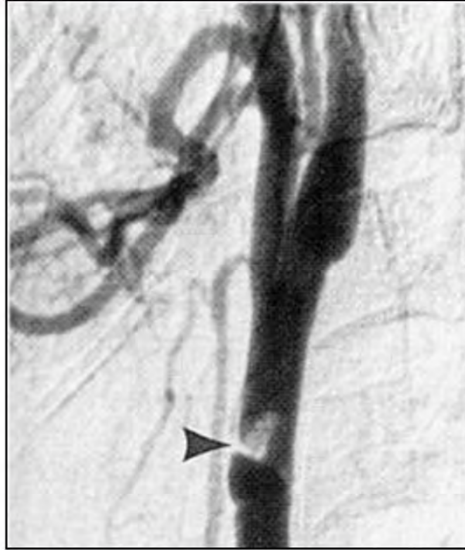
Common carotid:

- In general, vessels should be repaired rather than ligated
  - The subclavian and internal jugular veins can be ligated without adverse effect
  - Major arteries should be repaired where possible except the vertebral which can be ligated
  - Carotid injuries should be repaired unless there is an already established dense neurologic deficit w/ edema
  - Ligation in neurologically intact for high internal carotid injury if very difficult or impossible to gain access and repair timely
  
- Recognize revascularization may convert ischemic to hemorrhagic infarct
  
- If bypass is needed, PTFE preferred over saphenous vein graft; Saphenous vein graft may be used; Shunting is rarely necessary; Thrombectomy may be necessary

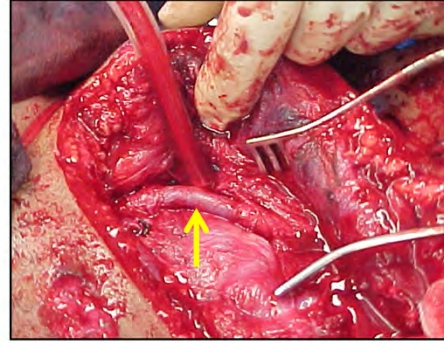
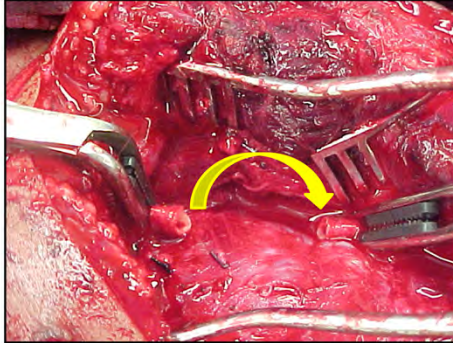
Partial lacerations can be closed primarily -- vein patches will help prevent subsequent stenosis

NOTE: High velocity wounds produce a surrounding area of contusion which may be thrombogenic and which must be resected; then primary reanastomosis if possible

## Carotid Intimal Flap



## Carotid Artery Interposition Repair



## Management Summary

### Vascular Injury

- Surgical exploration unstable and stable Zone II
- Angiography for Zone I and III
- Selective, nonoperative management stable Zone II
- Embolization high carotid or vertebral artery
- Endovascular stent (pseudoaneurysms)
- Anticoagulation blunt carotid/vertebral artery



- The old standard was formal neck exploration for all penetrating trauma that violates platysma, however, there was a 50% negative exploratory rate, so the new focus became directed exams to determine extent of injury with possible observation in hemodynamically stable patients without evidence of injury.
- Nonoperative management with close observation depends on expertise and facilities.
- Endovascular stenting is useful if vessel is difficult to access surgically such as those Zone III injuries.
- Anticoagulation may or may not be possible depending on other injuries, e.g. TBI.

37-58% of patients have permanent neurologic deficits on discharge though early use of antithrombotic therapy has essentially eliminated ischemic events in asymptomatic patients with carotid artery dissection.

## Aerodigestive Injuries

- Airway structures
  - Trachea
  - Larynx
  - Thyroid cartilage
- Esophagus
  - If diagnosis < 24 hours
  - Poor outcome if diagnosed > 24 hours
- Pharyngeal



Aerodigestive injuries include the airway and upper digestive (gastrointestinal) tracts.

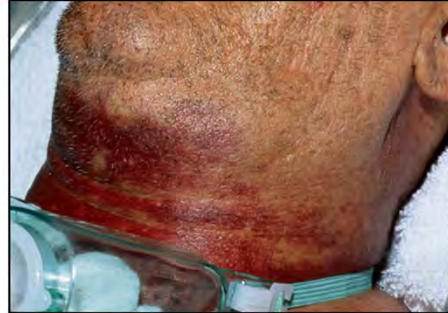Airway injuries occur more commonly with blunt mechanisms



## Tracheal and Laryngeal Injuries

### Signs of injury

- Hoarseness and dysphonia
- Hemoptysis
- Subcutaneous emphysema in the neck and trunk
- Tenderness over the trachea



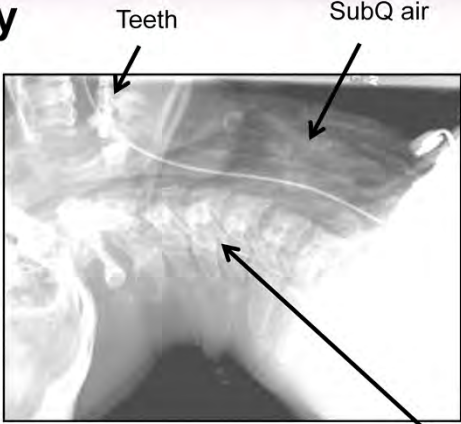
Dysphonia is any impairment to the voice. Hoarseness is a type of dysphonia. Patients with tracheal injury will often have subcutaneous emphysema that tracks down into their chest. They are often exquisitely tender over the trachea.

This x-ray shows extensive subcutaneous emphysema in the anterior neck


## Primary Diagnostics

### Laryngotracheal Injury

- Plain x-rays
  - Soft tissue emphysema
  - Airway compression
  - Fracture of laryngeal cartilages
- CT scan
  - 3D reconstruction
- Endoscopy
  - Flexible vs. rigid
  - Bronchoscopy/laryngoscopy



The image is a chest x-ray with three arrows pointing to specific features: 'Teeth' at the top, 'SubQ air' in the upper chest area, and 'Cervical Spine' at the bottom. The x-ray shows the skeletal structure of the chest and neck, with a white line representing the airway. There is a visible area of increased radiolucency (darker area) in the upper chest, indicating subcutaneous air.



The chest x-ray and plain film of the neck are sometimes useful as a screening tool for identifying free air. The CT of the neck is the most definitive diagnostic for tracheal/larynx injuries.

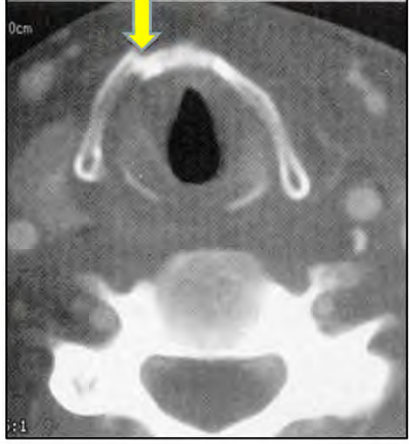
CT images provide detailed and accurate appraisal with advanced 3D reconstruction

Bronchoscopy is 100% accurate in diagnosing injuries


## Management

### Laryngotracheal Injury

- Secure the airway
- Early repair
- Laryngeal fractures
  - Thyroid fracture most common
  - Delay of reduction makes it more difficult and return of normal function unlikely



The image is an axial CT scan of the neck at the level of the larynx. A yellow arrow points to a clear fracture line in the thyroid cartilage, which is the large, shield-shaped cartilage anterior to the larynx. The airway is visible as a dark space in the center. The surrounding bony structures, including the vertebrae and other cartilages, are visible in white.





- Intubation with RSI is safe in the majority of patients, however, when necessary, a surgical airway may be utilized. Tracheostomy if unstable.
- If air emanates from a penetrating cervical injury, the patient may be intubated through the neck injury directly into the tracheal lumen. About 25% of reports indicate this is successful. However, attempts may be futile and precipitate total obstruction or allow the progressive loss of an unstable airway if repeated attempts are unsuccessful.
- Timely repair of certain injuries is important to prevent long-term complications such as chronic pain, stenosis, or voice change.
- Most have some permanent voice and airway impairment or tendency to aspirate.
- Postoperatively – aggressive pulmonary toilet, frequent bronchoscopies are key. Patients may have difficulty with pulmonary toilet if unable to have a productive cough secondary to vocal cord paralysis. Some may have issues with aspiration due to difficulty in elevating the larynx during swallowing.
- This photo is of a fractured thyroid.

## Esophageal Injury

**Penetrating**

- Sharp weapon (knife)
- High speed projectile (bullet)
- Iatrogenic laceration
- Lumen outward injury



Esophagus originates at end of laryngopharynx (C6 level). Injury is rare. When at rest, the esophagus relaxes and decreases in size making it small and less prone to injury



Penetrating esophageal injury can be divided into 4 types. The first is with a low velocity weapon such as a knife. The second is a high speed projectile like a bullet or arrow. The 3<sup>rd</sup> is caused by an endoscope or by esophageal dilation (treatment for stricture). The 4<sup>th</sup> type of injury is from the inside out (ingestion of razor, fish bones, etc.)

This patient has a knife wound to the neck and is at high risk for esophageal injury

## Esophageal Injury

**Blunt**

- Barotrauma
- Blast injuries
- Crush injuries
- Blow to the neck



### Blunt trauma

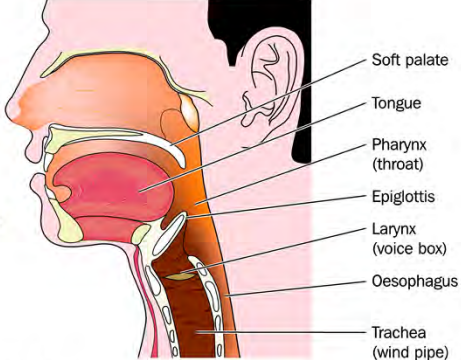
Barotrauma is a rapid change in the pressure of the esophagus which leads to tearing or perforation. Examples of this includes blast injuries. Another example of barotrauma is Boerhaave's syndrome where a patient vomits against a closed glottis, resulting in increased pressure in the esophagus causing perforation. Crush injuries are also another mechanism for blunt esophageal injury as are blows to the neck during fights/boxing matches.



## Esophageal Injury

**Signs of Injury**

- Hematemesis
- Odynophagia
- Dysphagia
- Drooling, hypersalivatio
- Tracheal deviation
- Sucking neck wound
- Subcutaneous emphysema
- Pain with turning neck



**STN**  
SOCIETY OF TRAUMA NURSES

As previously mentioned, failure to identify the esophageal injury, if delayed > 24 hours, has a significantly increased morbidity and mortality rate (overall mortality 19% per Asensio paper 2001 Journal of Trauma. )


Esophageal injuries are often very subtle and difficult to diagnose. Some of the signs associated with esophageal injury include the following.

- Often clinically silent
- Milder subcutaneous emphysema
- Hematemesis. Patients may have bloody emesis or saliva.
- Odynophagia is extreme pain with swallowing.
- Dysphagia is an inability to swallow.
- Excessive drooling and inability to swallow saliva is a key sign. Patients will often have excessive saliva production as well.
- Fever (late)



## Esophageal Injury Diagnostics

<b>Radiographic Findings</b>	<b>Laboratory Findings</b>
<ul style="list-style-type: none"><li>• Plain films<ul style="list-style-type: none"><li>• Air in soft tissue planes</li><li>• Pneumomediastinum</li><li>• Leakage of fluid into right pleural space</li></ul></li><li>• Contrast swallow<ul style="list-style-type: none"><li>• Extravasation is diagnostic</li></ul></li><li>• CT scan</li></ul>	<ul style="list-style-type: none"><li>• Markers of inflammatory response<ul style="list-style-type: none"><li>• Leukocytosis with left shift</li><li>• Low oxygen saturations</li><li>• Acidosis on ABG</li></ul></li></ul>



Lab studies will show a patient with an increased WBC count and metabolic acidosis due to impending infection.

Plain films of the neck might show free air in the soft tissues of the neck as well as a right sided pleural effusion as the esophageal perforation leaks into the right pleural space. This is a very late sign. Negative study is not reliable (particular in neck with gastrografin)

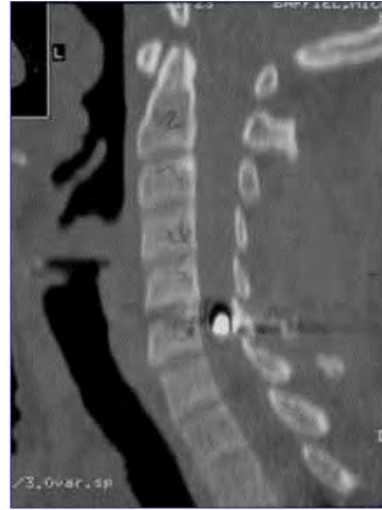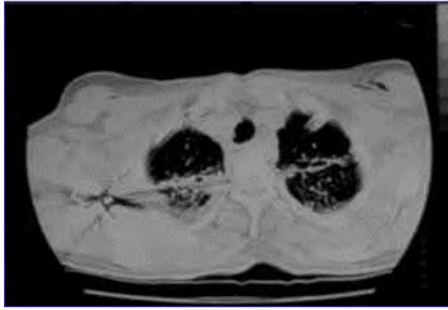
50% of leaks missed with gastrografin

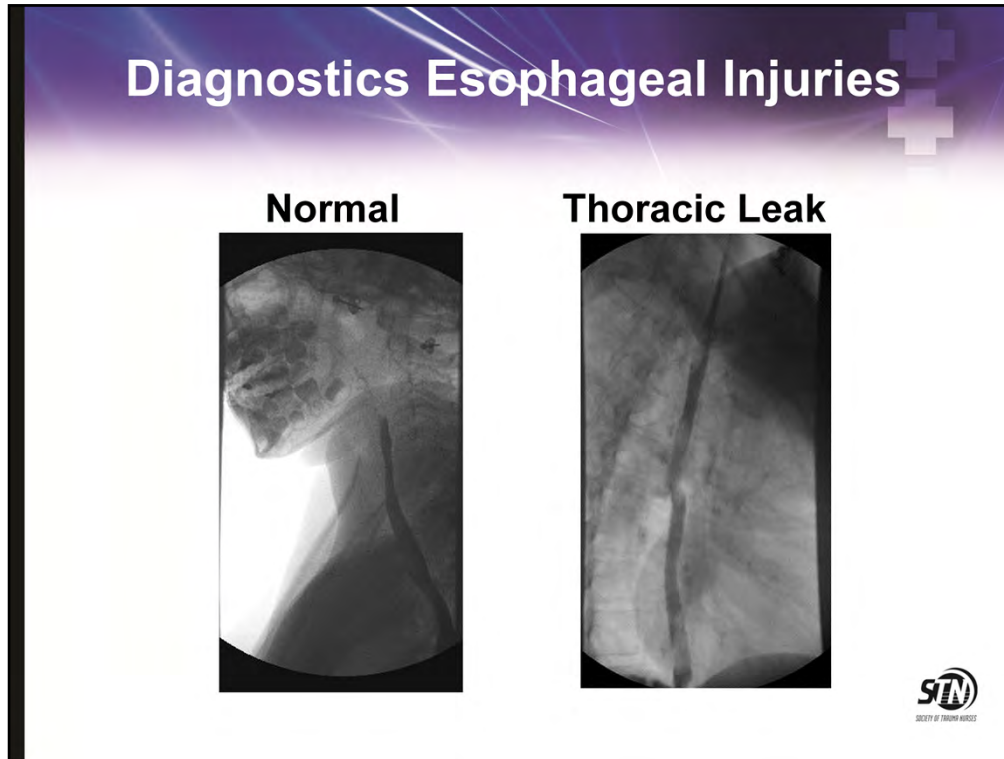
25% of leaks missed with barium

## Esophageal Injury Diagnostics

### Helical CT

- Expedites diagnosis
- Trajectory of missile
- Associated injuries





Contrast esophagography (using Gastrografin), Esophagoscopy, or Both

- The picture on the left shows a normal gastrografin study.
- This picture demonstrates a gastrografin esophagography. It shows a leak in the thoracic esophagus.
- Combining esophagography with esophagoscopy increases the likelihood of identifying the small perforation, though these studies still may not identify the injury if it is small.
- Combination of swallow/esophagoscopy reduces missed injuries to < 5%
- 50% perforations missed (Weigelt et al Am J Surg 1987) in pharynx and cervical esophagus.
- May also be missed in patients on ventilator (poor expansion of esophagus)

Contrast swallow


Extravasation is diagnostic

Negative study is not reliable (particular in neck with gastrografin)

50% of leaks missed with gastrografin


25% of leaks missed with barium

## Esophageal Injury



### Management Summary

- Initial assessment complex
- Goal is to minimize the bacterial contamination and enzyme erosion
- Gastric decompression
- Antibiotic coverage
- Drainage of wound
- Surgical repair

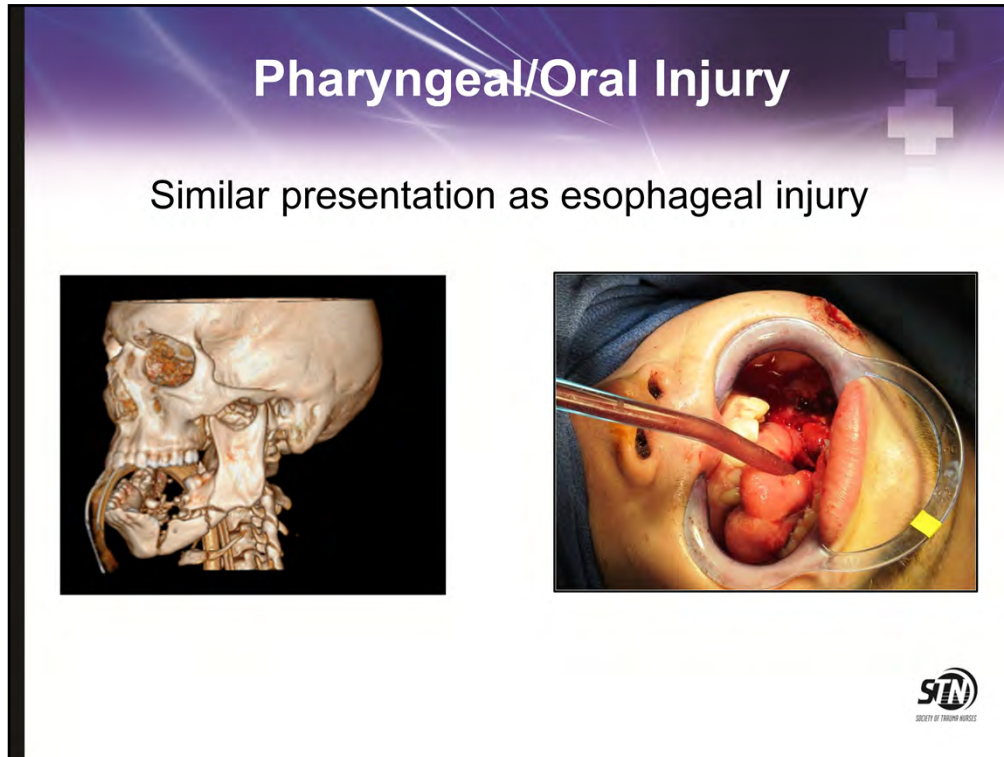


Evaluation is difficult as esophageal injuries are rare and usually occur in conjunction with other injuries. Depending on the extent of injury, different surgical techniques may be employed to repair esophageal tears.

A primary repair is the gold standard of care and should be utilized for visualized perforations of the cervical esophagus as well as perforations of the thoracic and abdominal esophagus.

These surgical principles include a careful dissection to isolate the esophagus without damaging vital structures, evacuation of debris and devitalized tissues, and debridement of the area of perforation.

Delayed diagnosis results in significant morbidity and mortality.



This picture demonstrates a significant tongue and pharyngeal injury due to a gunshot wound to the mandible that crossed through the mouth. In this case, oral bleeding and hemoptysis would be anticipated. Airway compromise could be a potential issue.


Usually diagnosed with a naso-pharyngeal scope

May have Gastrografin swallow followed by Barium if negative

Flexible ± rigid esophagoscopy

## Practice Guidelines

- Few published practice guidelines for the management of neck injuries
- Eastern Association for the Surgery of Trauma (EAST)
  - Penetrating neck injuries only
  - Blunt cerebrovascular injury




EAST has the only formal, nationally circulated practice guideline relating to neck trauma. It is a very specific guideline that deals only with PENETRATING injury in ZONE II of the neck.

We will review it to identify key points in managing penetrating injury. There are no similar guidelines for management of blunt neck trauma or other specific types of neck trauma available.



## EAST Guidelines Key Points

- Selective operative management vs. mandatory exploration
- CT Angiography and duplex ultrasound can be used to identify Zone II arterial injuries
- Plain CT of the neck can be used to rule out a significant vascular injury
- Contrast esophagography or esophagoscopy can be used to evaluate for perforation.
- Serial physical examination is 95% sensitive for detecting arterial and aerodigestive tract injuries that need repair



This is the only recommendation that is based on Class 1 (prospective, randomized double-blinded study).

*Class 1 Evidence- based on class I data, were meant to be convincingly justifiable on scientific evidence alone*

This is considered the most sound data available on which to base practice.

This “grading system” methodology is based on the methodology used by the Agency for Health Care Policy and Research of the US Department of Health and Human Services.

**In this case, “selective” surgical management is as acceptable as operating, so this guideline encourages surgeons to adopt the “selective” approach.**

CT angio and duplex use - This demonstrates the move away from using formal angiography for diagnosis of these injuries.

Class II evidence is based upon prospective, randomized, non-blinded trials

Plain CT of the neck (without CT angiography) can be used to rule out a significant vascular injury if it shows that the path of the penetrating object is not in proximity to vital structures. When injuries are close to vascular structures, minor vascular injuries such as intimal flaps may be missed. (Class III evidence)

Class III data is based on retrospective studies or meta analysis studies

Contrast esophagography or esophagoscopy can be used to evaluate for perforation.

> 24 hours delay in recognition of esophageal injury result in dramatically increased mortality

Level 2 recommendation

Overwhelming mediastinal infection is the often the outcome if there is a delay in diagnosis of esophageal injuries.

Serial physical examination, including auscultation of the carotid arteries, is 95% sensitive for detecting arterial and aerodigestive tract injuries that need repair

Class III data is based on retrospective studies or meta analysis studies.

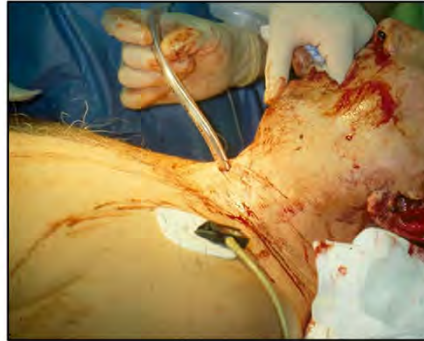## EAST Guidelines Summarized

- Selective management is common now in asymptomatic patients;
- CT angiography is a very good tool to rule out vascular injuries
- The role of physical exam, esophagography, and esophogoscopy remains controversial



## Do all patients have to lay flat?

- Position patient in manner that is most comfortable
- Patients with anterior neck trauma may want to lean forward or sit upright
- Patients with copious secretions can be rolled on their side



Patients with penetrating injuries are at lower risk for thoracic and lumbar spine injuries. They can be positioned for optimal comfort and airway patency. There is no rule that all patients must be positioned supine as they are not high risk for spine injury.

Cervical spine immobilization is not always indicated in penetrating trauma to the neck. Recent literature indicates that the previously taught/mandated cervical spine immobilization for penetrating trauma to the neck is not indicated and could be harmful considering the amount of time wasted to immobilize rather than “scoop and run” in situations of life/death. Also, as previously mentioned, airway may be positional. Many still believe it is appropriate to consider immobilization for patients who are victims of penetrating neck trauma demonstrating neuro deficits, however, others believe that the damage has been done and that immobilization will not benefit the patient.

This patient, before his airway was protected with a cricothyroidotomy, was unable to protect his airway when laying flat on the gurney.

## Possible Complications

- Loss of airway
- Swallowing problems with aspiration
- Stroke in unrecognized vascular injuries
- Soft tissue necrotizing infections, including mediastinitis due to delayed diagnosis of esophageal injuries
- Air embolism
- Pneumothorax, tension pneumothorax



### Airway compromise

Injuries to the larynx may cause one to have issues with swallowing, and as a result, aspiration.

There are several associated injuries that increases one's risk for having BCVI. The earlier recognized, the earlier sequelae can be minimized.

Delay in recognizing esophageal injuries can be deadly.

Open wounds to neck vein bleed heavily or allow air to enter the circulatory system.

## Nursing Considerations

Be alert for:

- Mental status changes and motor deficits
- Changes in airway patency
- Onset of stridor, drooling
- Difficulty laying supine
- Other injuries that are highly associated with cerebral vascular injuries



As previously noted, mental status changes can be a sign of cerebral vascular injury  
Air hunger indicates impending loss of airway

Note: Not all patients need to lay flat! Patients with air hunger can have the head of the bed elevated, can be rolled on their side, or positioned in whatever position is comfortable for them.

## Nursing Assessment

- Frequent neurologic and motor checks
- Frequent assessment for expanding hematomas in the neck
- Careful history documentation
- Reassurance
- Adequate pain assessment
- Anxiety reduction



Reassurance is very important because patients with laryngeal or tracheal injury, may have stridor and anxiety will increase their hypoxia. Proper positioning in the airway compromised patient can dramatically reduce anxiety.



## Summary

- Penetrating and blunt neck trauma occurs in 5-10% of patients with serious injuries
- Maintenance of an adequate airway is paramount to survival
- Maintain a healthy respect for initially benign appearing injuries
- Unrecognized vascular or aerodigestive injuries have a high mortality

