



# Synchronous Pseudovascular and Spindle Squamous Cell Carcinoma in the Maxillary Sinus; A unique case report and review of literature



Guofeng Gao, MD PhD; Amir Ghorbani-Aghbolaghi, MD; Regina F. Gandour-Edwards, MD; Morgan A. Darrow, MD

Department of Pathology and Laboratory Medicine, UC Davis Medical Center, Sacramento, CA

## INTRODUCTION

Spindle squamous cell carcinoma (SpSCC) is a rare aggressive variant of squamous cell carcinoma (SCC) and accounts for 3% of all head and neck SCCs. SpSCC confined to the nasal cavity is very rare, with the majority of cases involving the maxillary sinus (male preponderance more common in the 5<sup>th</sup>-6<sup>th</sup> decade and strong association with smoking and alcohol consumption). Pseudovascular SCC is also an extremely rare aggressive variant of SCC that can mimic angiosarcoma and poses a diagnostic challenge. Here we present a case of pseudovascular and spindle cell variant of SCC in the maxillary sinus.

## CASE REPORT:

A 75-year-old lady was presented with sinus pressure pain and left maxillary numbness for several months. CT/MRI showed left maxillary sinus opacification and soft tissue mass. Following biopsies demonstrating SCC, a left total radical maxillectomy, left neck dissection level I-IV, and left fibular free flap reconstruction was performed. A 3.0 x 2.8 x 2.8 cm mass invading cortical bone was identified in maxillary sinus. Histological examination showed the mass comprised of fasciculated and streaming spindle cells with hyperchromatic and pleomorphic nuclei (Fig. 1) simulating sarcoma and areas with marked pseudovascular pattern. A diagnosis of spindle and pseudovascular SCC (T3N0) was made. Patient received adjuvant radiation therapy. No evidence of local recurrence or metastasis has been found in clinical and radiological studies within 8 months of work up.

Fig. 1 H&E (100X)

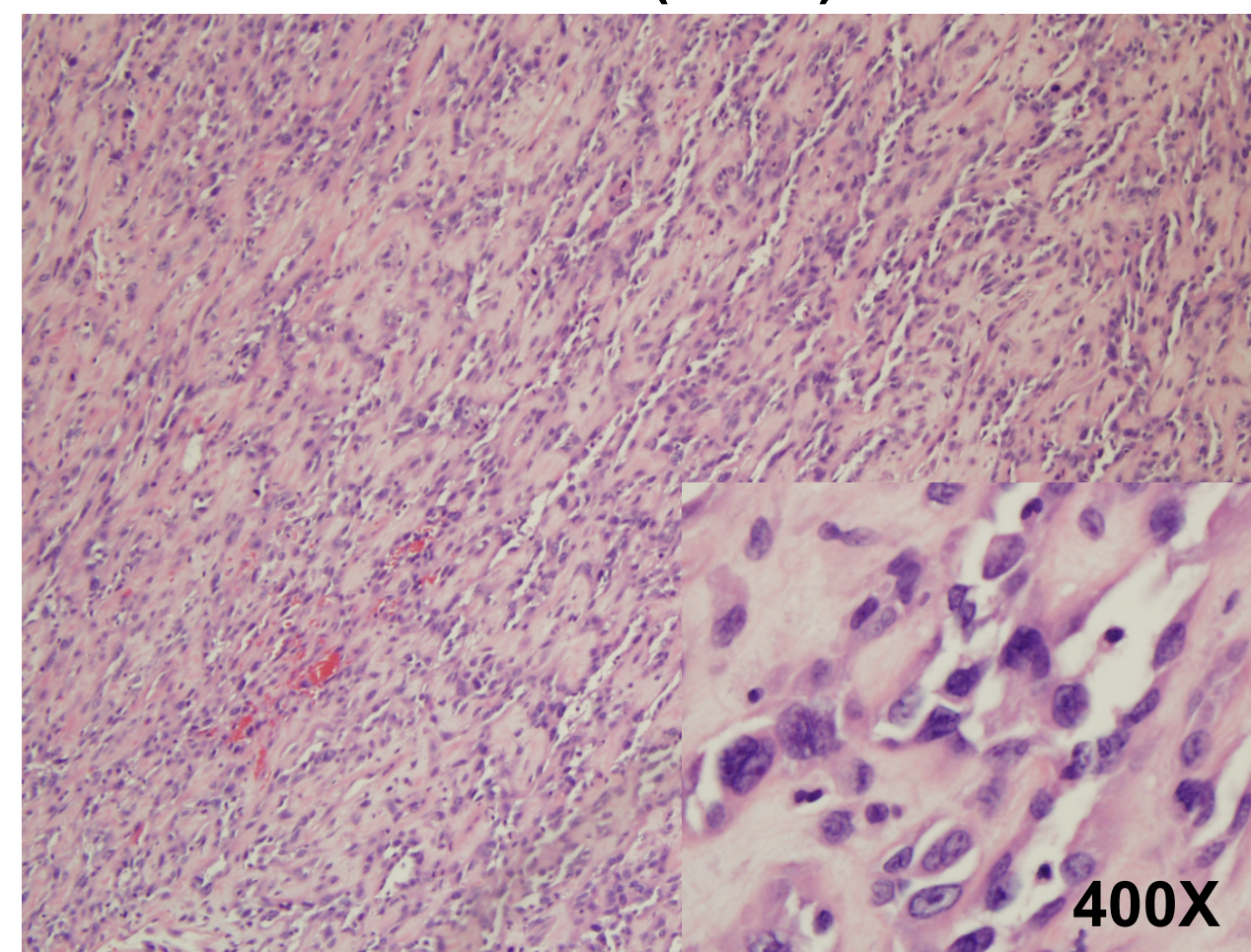


Fig. 2 AE1/AE3 (100X)

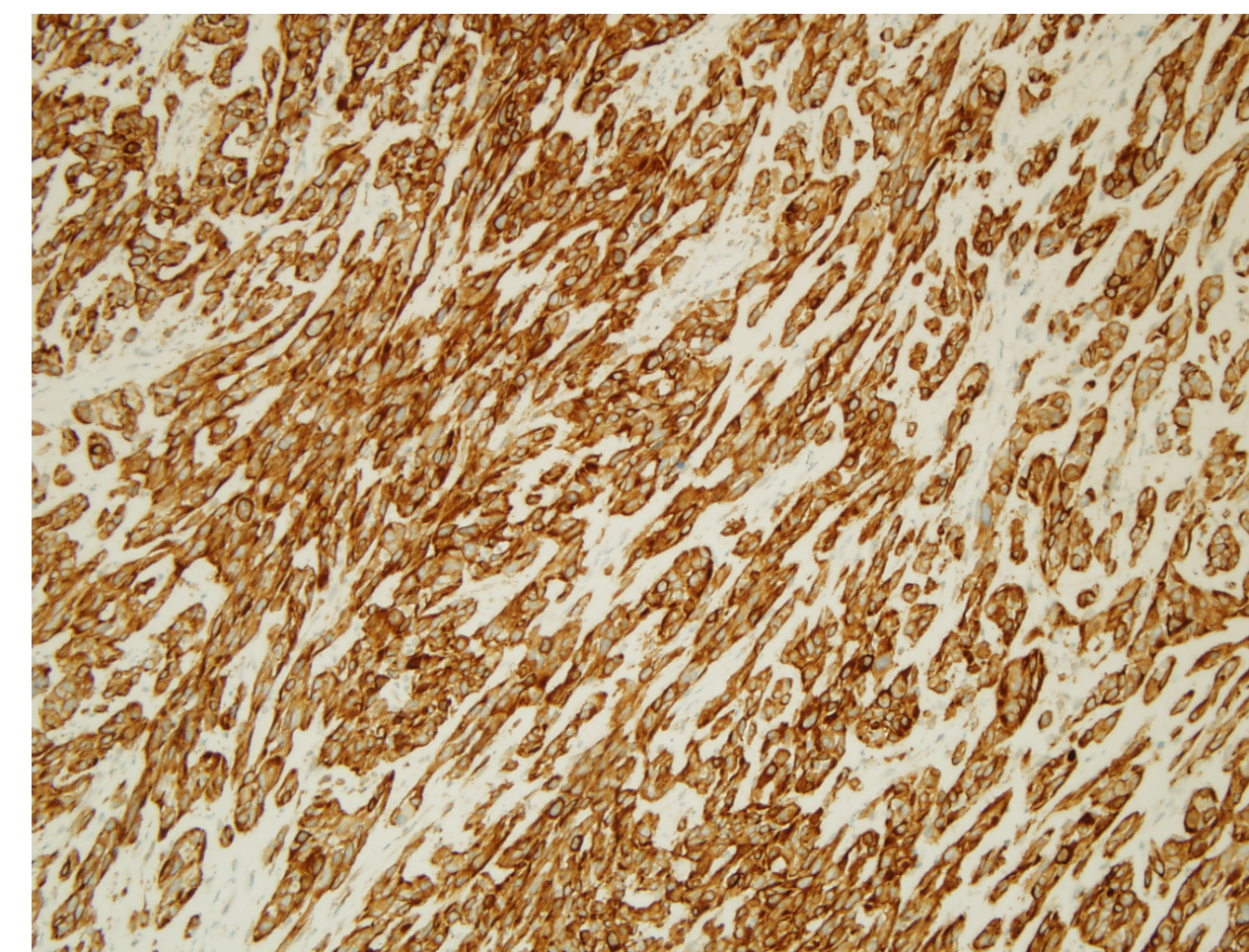


Fig. 3 CK5/6 (100X)

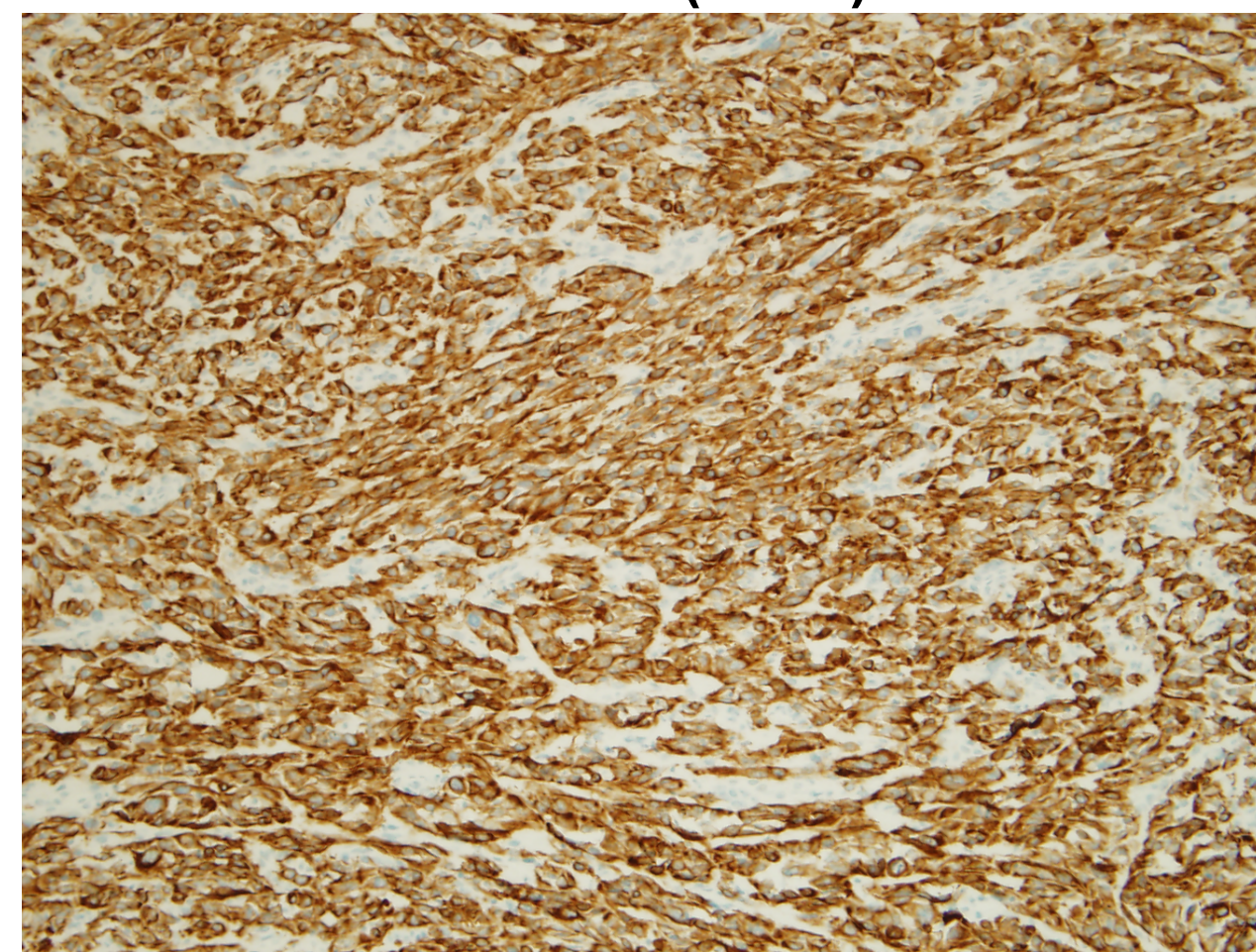
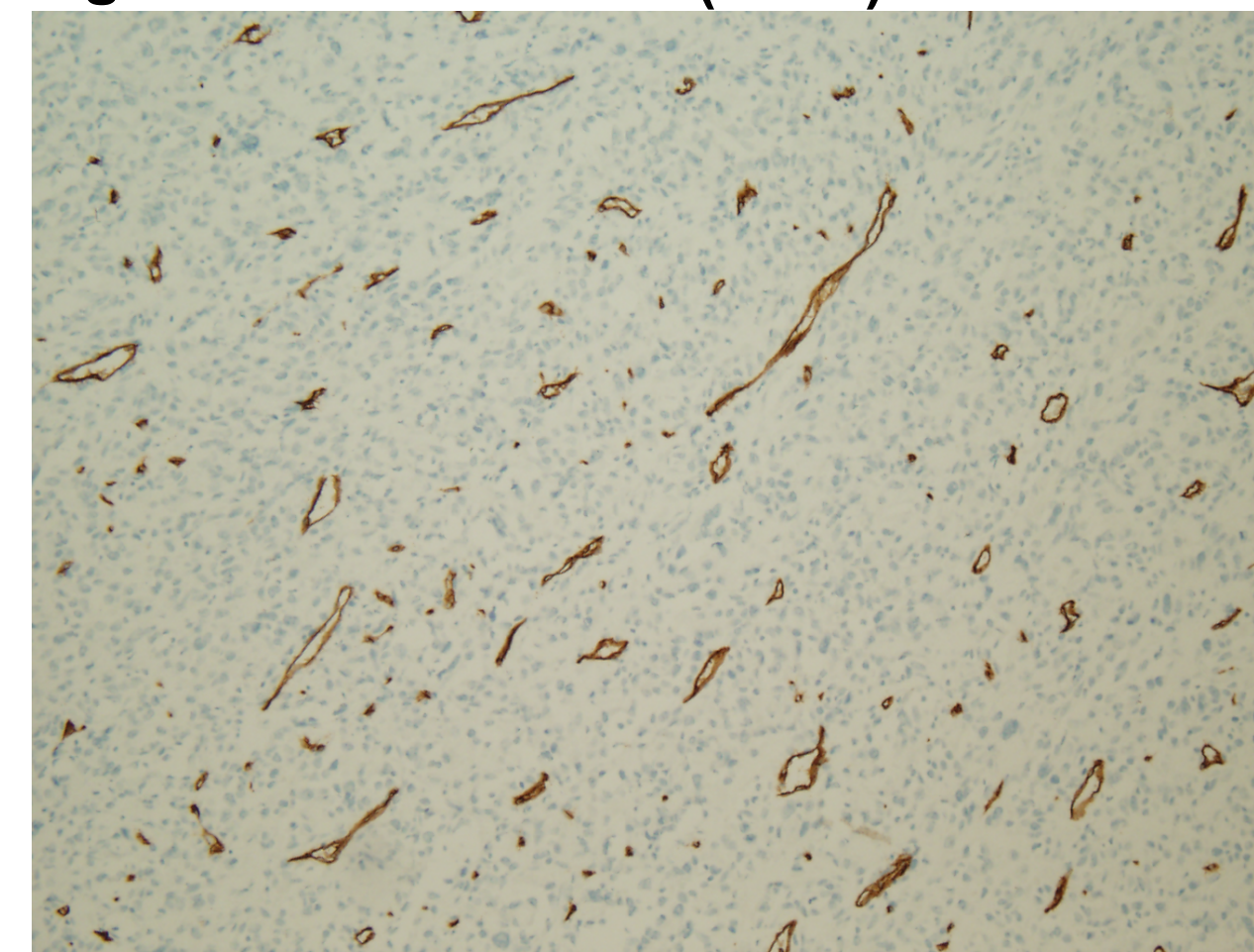


Fig. 4 CD34 (100X)



## DISCUSSION:

SCC has many variants to conventional ones: spindle cell, pseudovascular, basaloid, adenoid, papillary, verrucous, lymphoepithelial, and adenosquamous. The recognition of these variants is critical because most of them are true clinicopathological entities with key prognostic implication and they can mimic other neoplasms, resulting in erroneous treatment. Diagnosis of pseudovascular or spindle cell SCC is difficult owing to the rarity of such entity in general. Pseudovascular SCC is characterized by the formation of anastomosing spaces and channels with or without erythrocytes which mimics angiosarcoma. The fascicular and streaming spindle cells with pleomorphic and hyperchromatic nuclei mimic sarcoma, posing a diagnostic challenge. Immunohistochemical studies are of utmost importance for the correct diagnosis of both variants; both express epithelial markers, such as cytokeratin and EMA,

whereas angiosarcoma typically expresses vascular markers CD31, CD34 and VWF. IHC study of our case demonstrated tumor cells were positive for AE1/AE3 (Fig. 2) and CK5/6 (Fig. 3), but negative for CD34 (Fig. 4) and CD31, thus confirmed the diagnosis of pseudovascular and spindle cell SCC.

To the best of our knowledge, this is the first reported case of synchronous spindle squamous carcinoma and pseudovascular SCC in the maxillary sinus. PubMed search showed less than 100 cases of SpSCC previously reported in the nasal cavity. Pseudovascular SCC is also extremely rare and only a few cases has been reported in the head and neck region (none in the nasal cavity). Both variants are aggressive and associated with poor prognosis.

## CONCLUSION:

This case demonstrates the importance of a systematic approach (careful microscopic review and immunohistochemistry).

Because of the aggressive nature of both variants, patients with either variant usually are treated with aggressive, wide local excision and subsequent adjuvant radiation and/or chemotherapy.

## KEY REFERENCES:

- Liu TW, Hung SH, Chen PY. Sinonasal spindle cell carcinoma presenting with bilateral visual loss: A case report and review of the literature. *Oncol Lett.* 2016;12:401-404.
- Mistry P, Mittal A, Nagpal T. Spindle Cell Carcinoma of Nasal Cavity- A Case Report. *J Clin Diagn Res.* 2016;10(4):MD01-2.
- Vidyavathi K, Prasad C, Kumar HM, Deo R. Pseudovascular adenoid squamous cell carcinoma of oral cavity: A mimicker of angiosarcoma. *J Oral Maxillofac Pathol.* 2012;16:288-90.
- Zidar N, Gale N, Zuperc A, Dovsak D. Pseudovascular adenoid squamous-cell carcinoma of the oral cavity--a report of two cases. *J Clin Pathol.* 2006;59:1206-8.

Contact: [gfgao@ucdavis.edu](mailto:gfgao@ucdavis.edu)